



重点病种 骨性III度深覆合或3mm以上开合
——PAOO辅助严重深覆合的二次矫治

病案号：BZ000016-2021000005

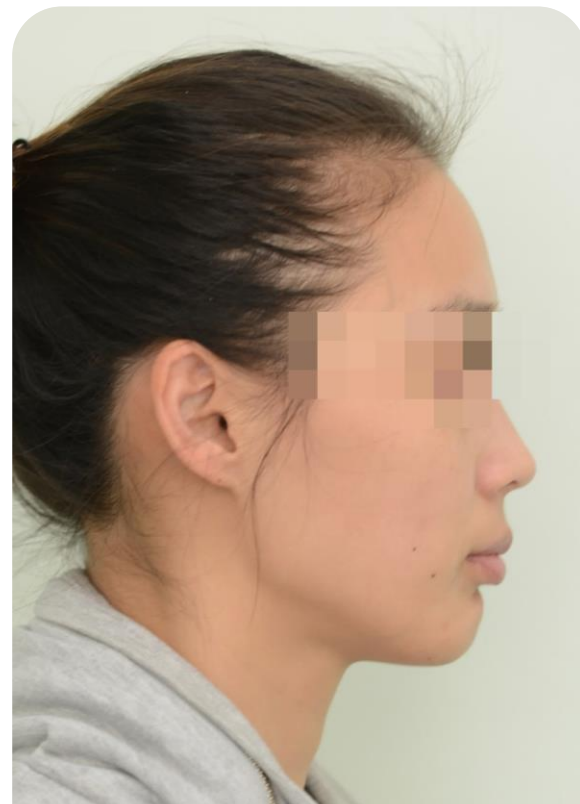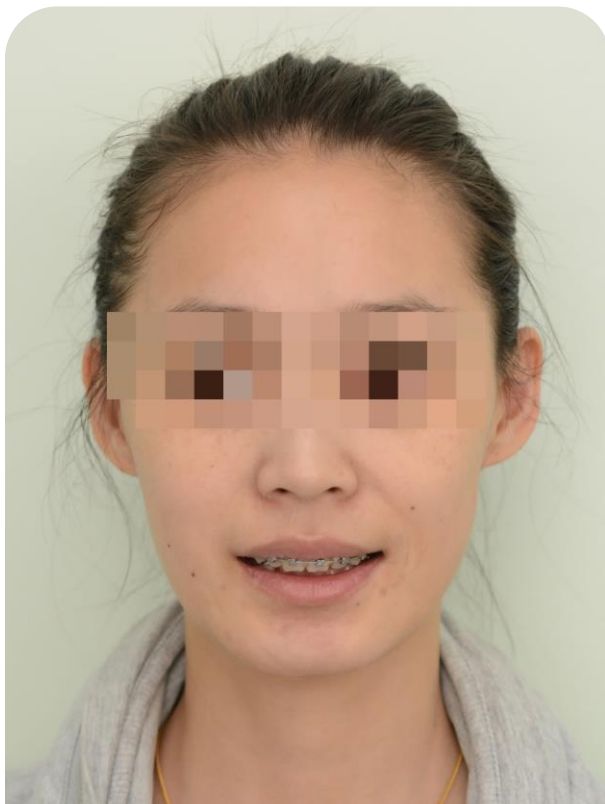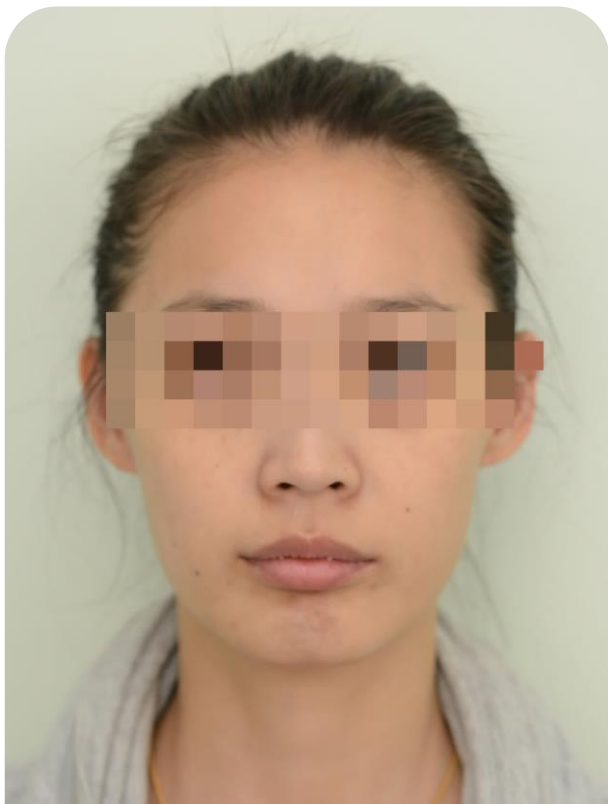
正畸医生：孙良葵





基本 资料

- 01 **王某，女，28y**
- 02 **初诊时间：2016-10**
- 03 **主诉：咬合深要求矫正**
- 04 **现病史：咬合深，牙齿不齐要求矫正，外院治疗一年后咬合进一步加深转至我院治疗。**
- 05 **既往史：否认系统性疾病，无药物过敏史，无金属过敏史**

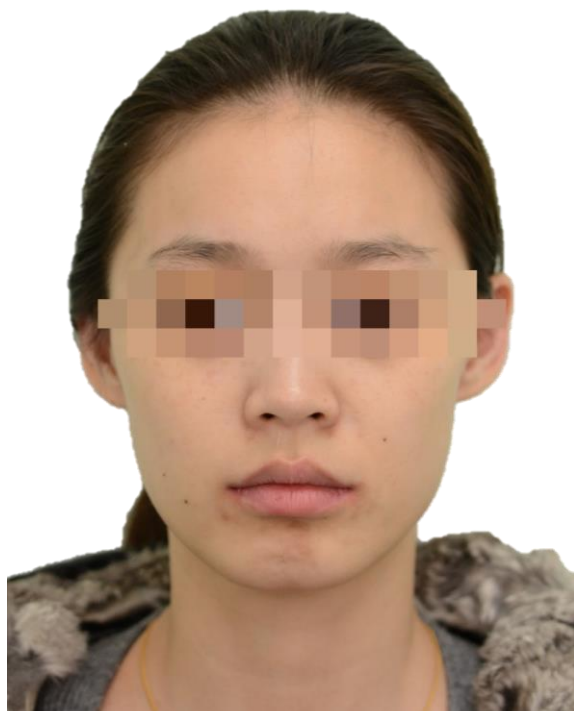

姓名：王某

性别：女

年龄：28岁

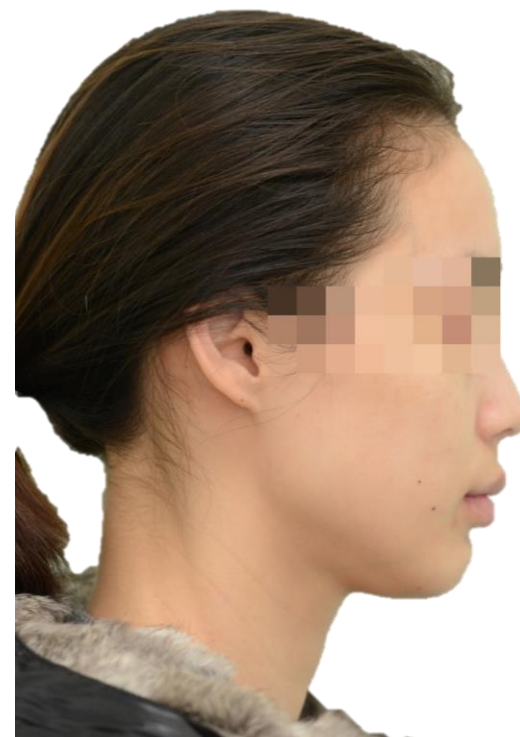主诉：上牙前突，不齐求治



职业：销售



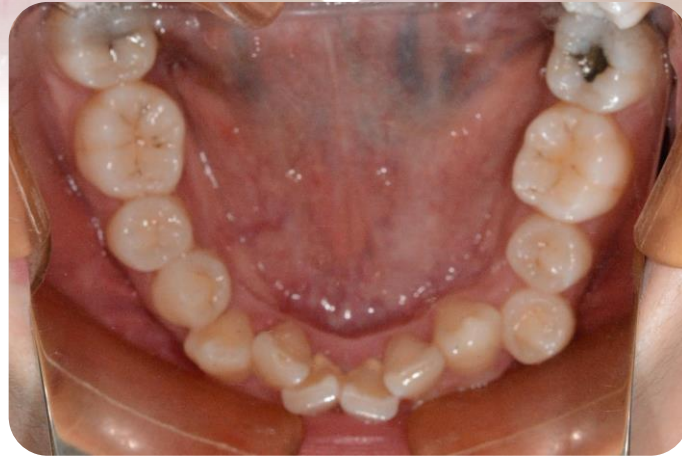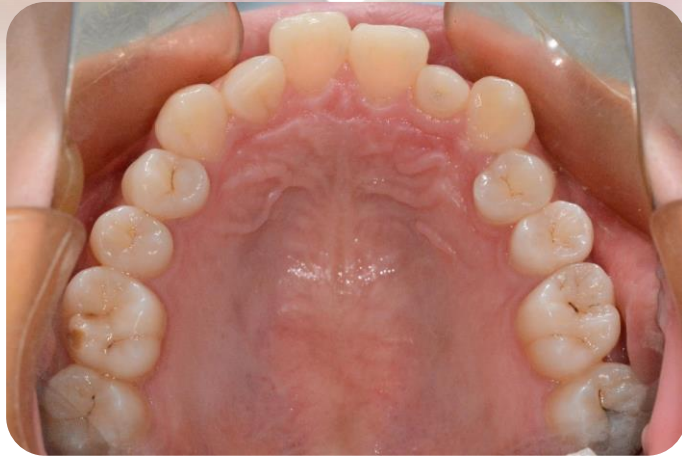
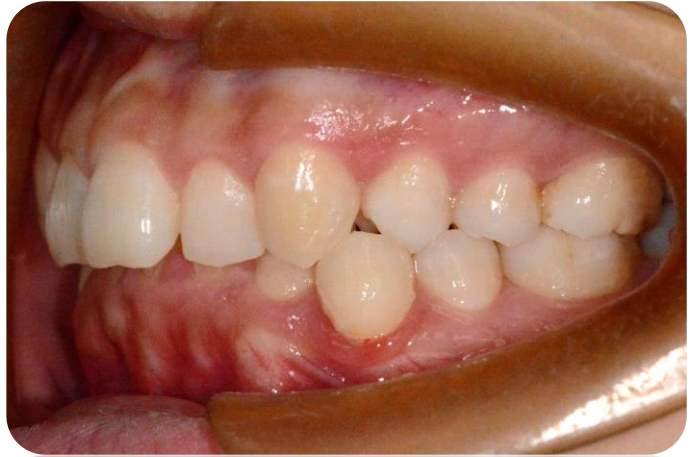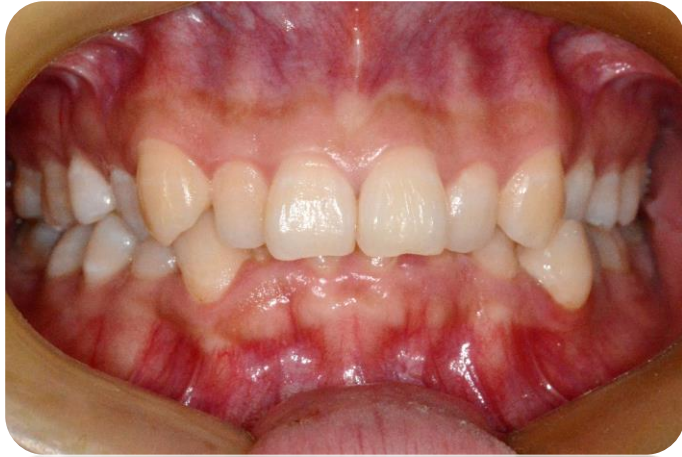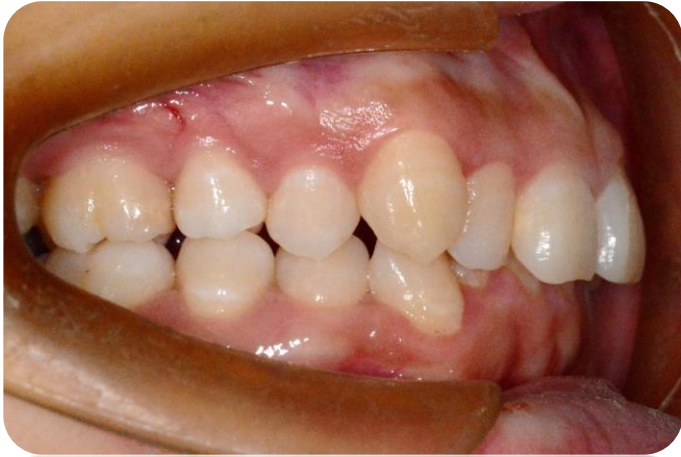习惯：经常熬夜



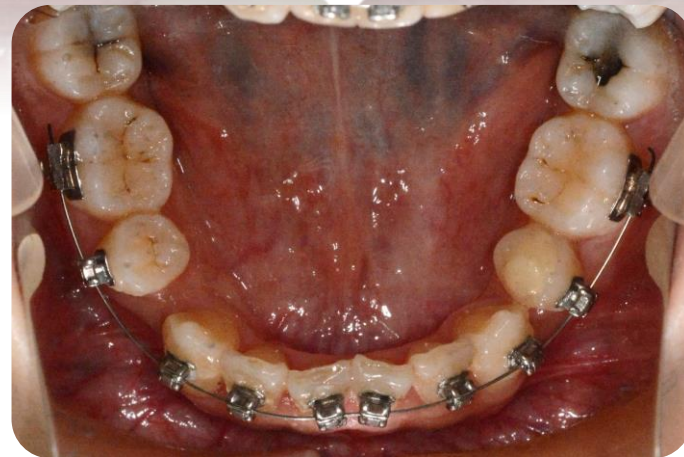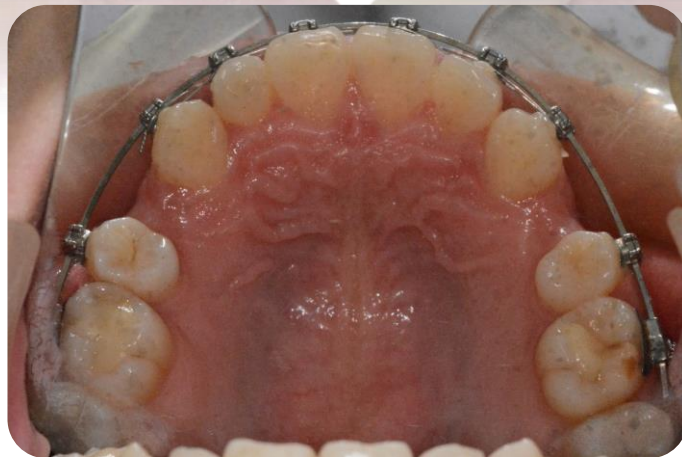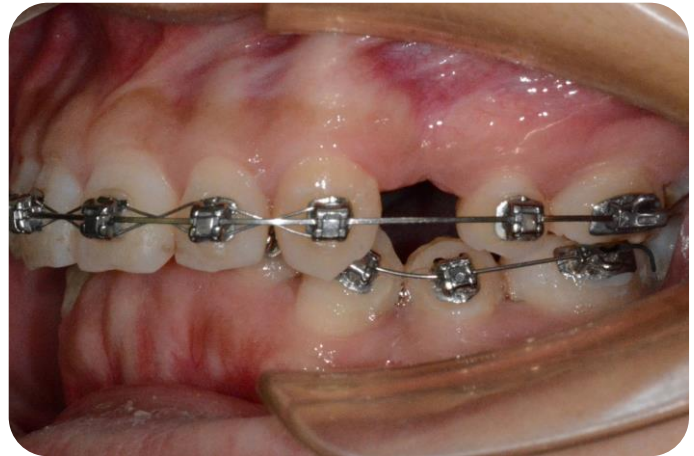
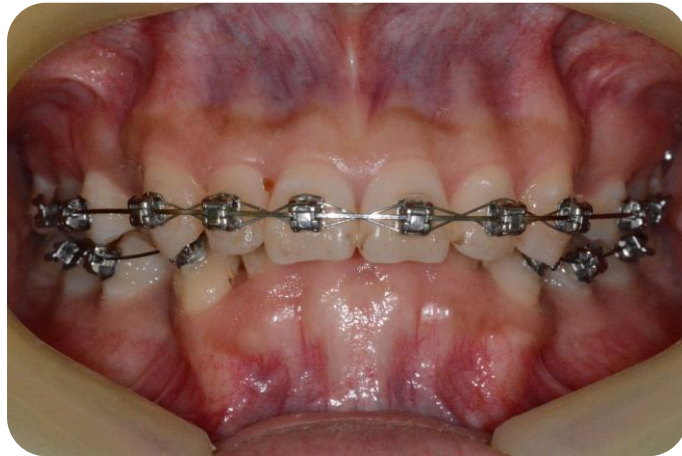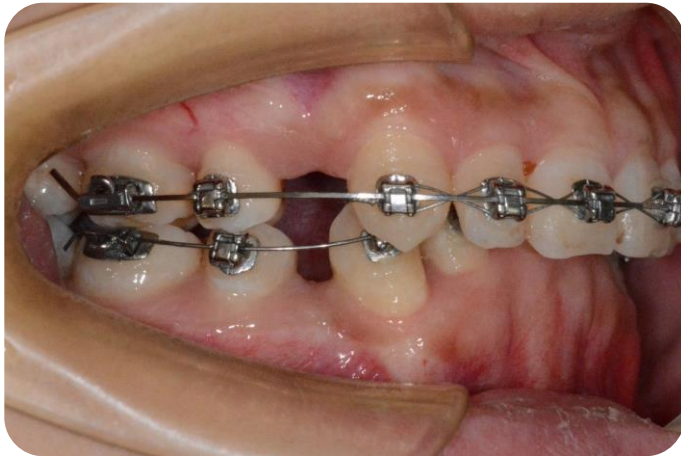
性格：宜人型

- 颞唇沟深
- 总体侧貌良好

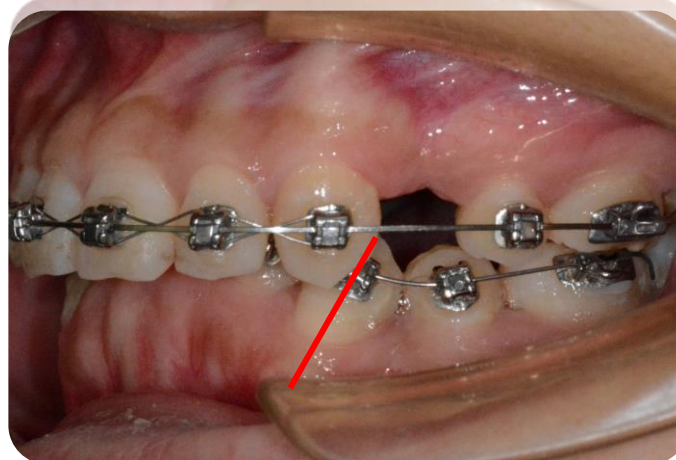
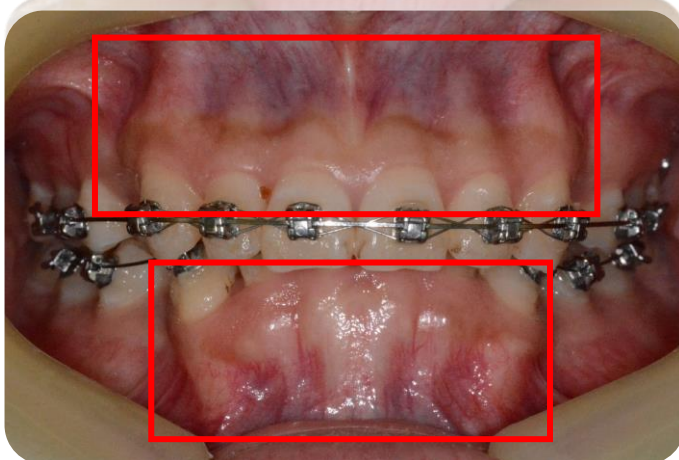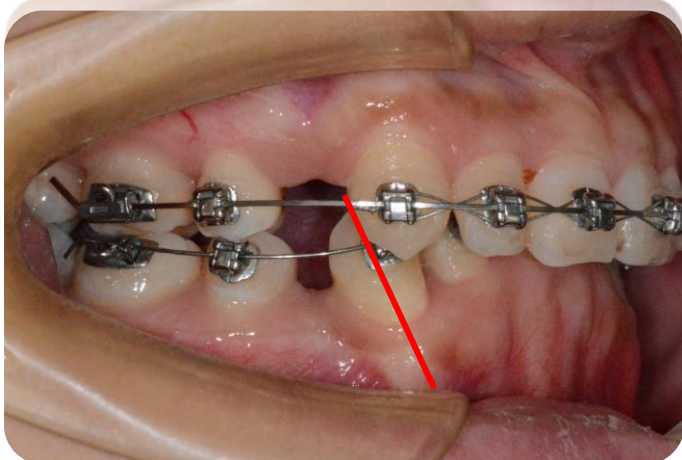
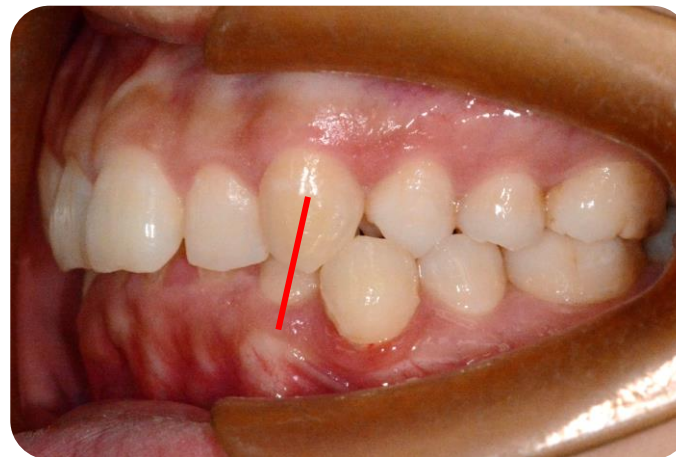
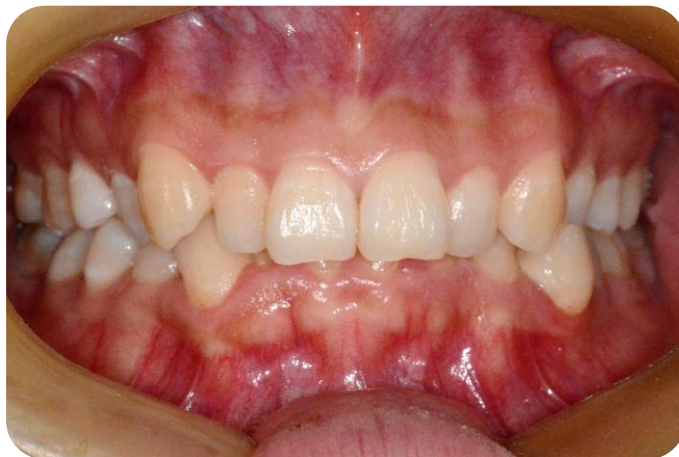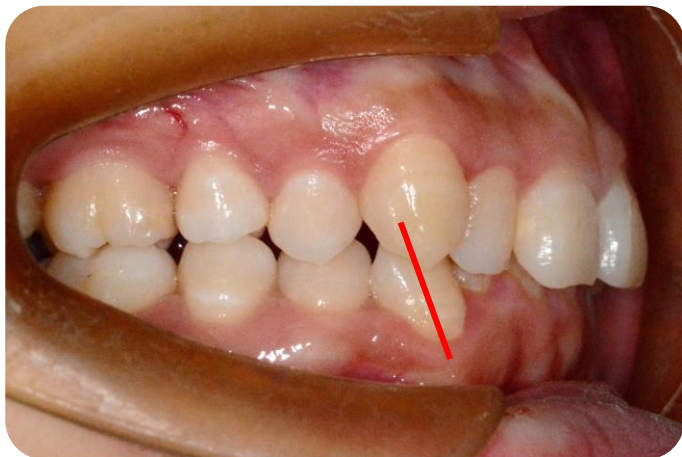正畸治疗前（初诊前一年）



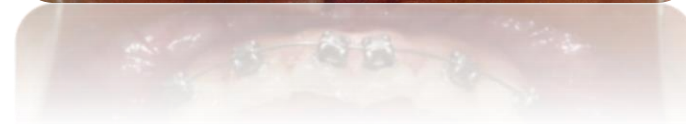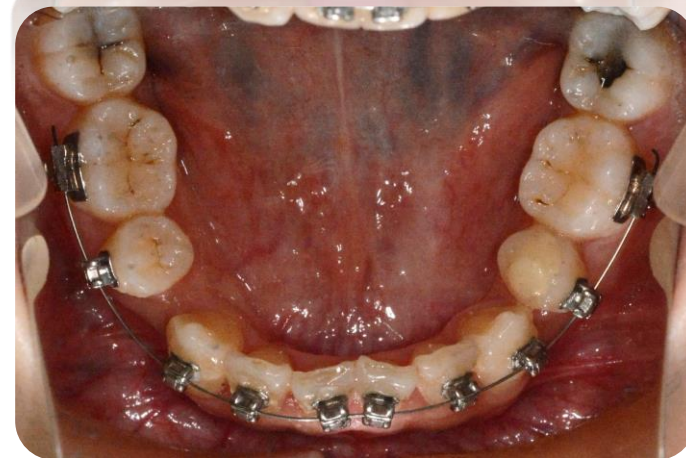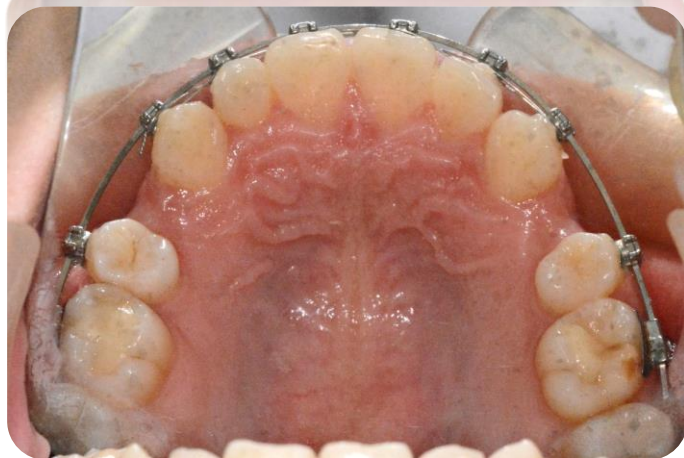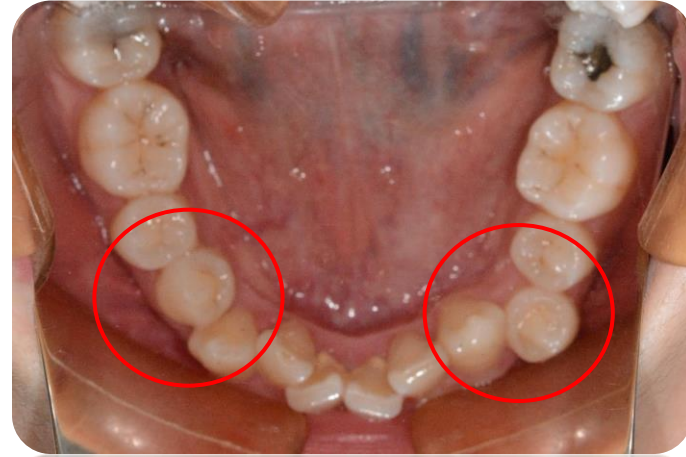
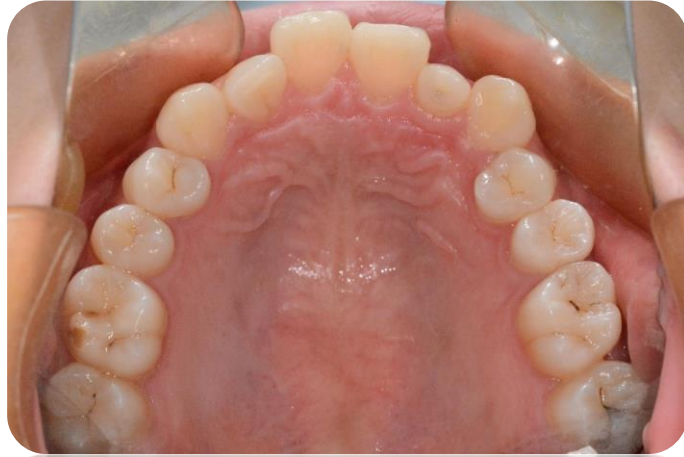1 year before first visit

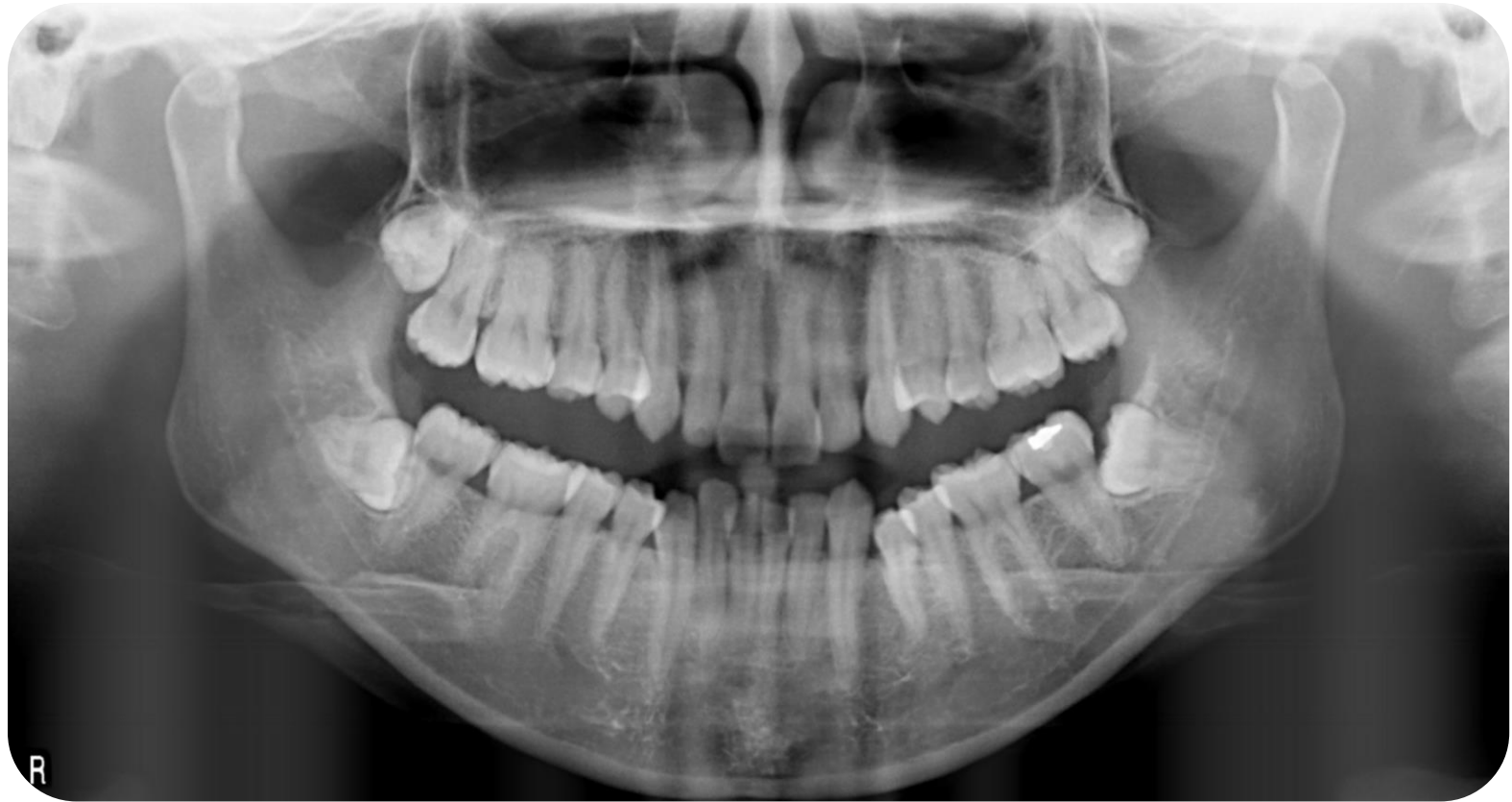

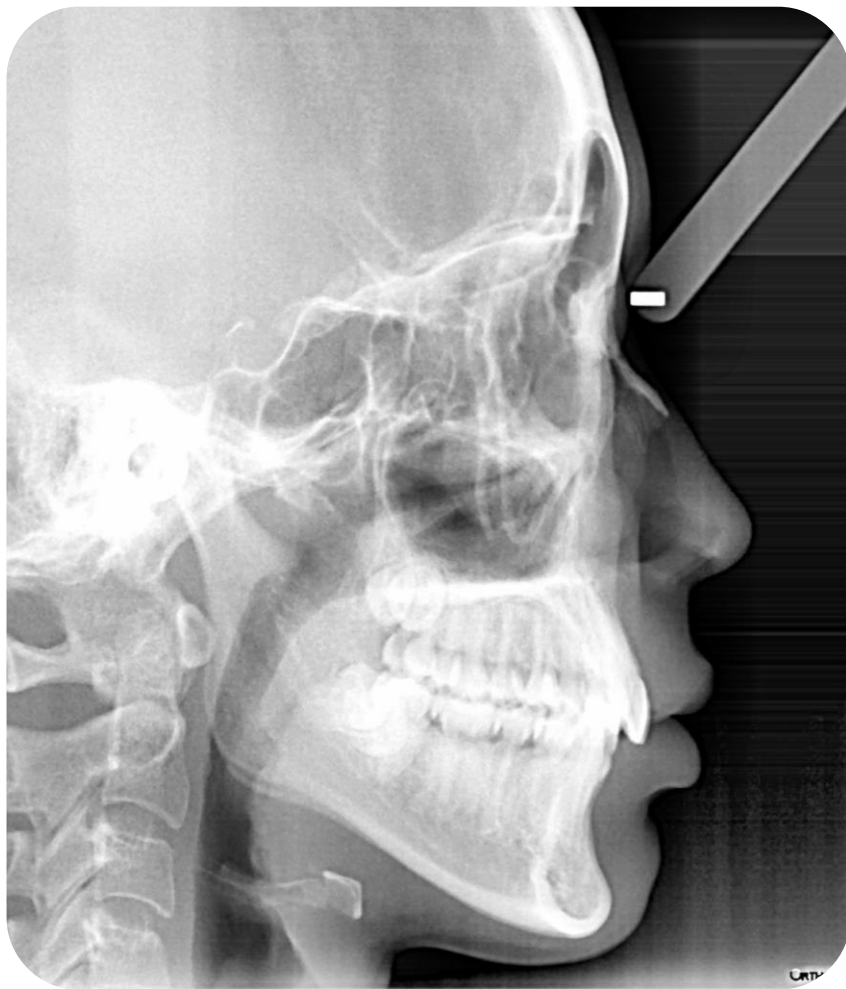
0 months



- 覆 进一步加深
- 根形暴露加重



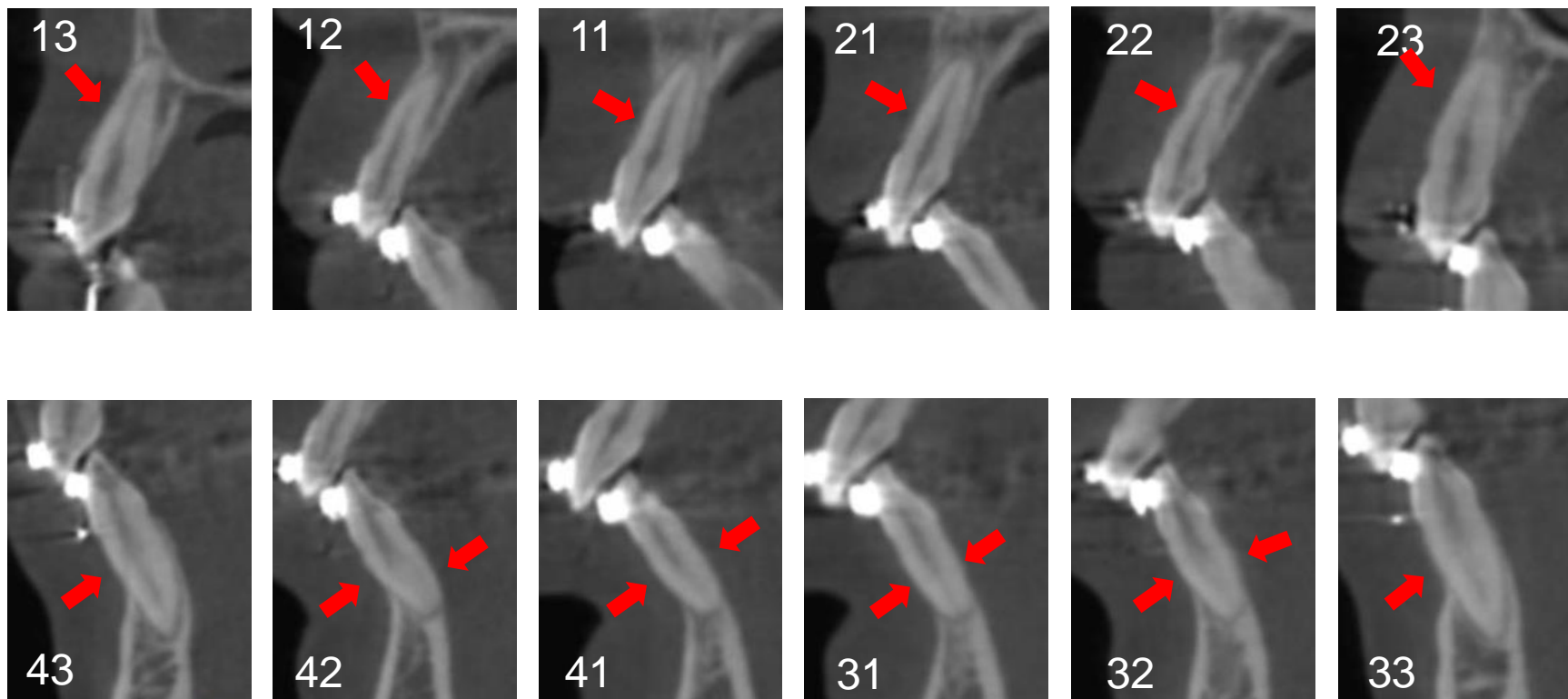




测量项目	治疗前	正常值 (LIU)
SNA	80.2	83.1±2.7
SNB	77.8	80.3±2.6
ANB	2.4	2.7±1.8
MP-SN	36.7	32.6±6.9
FH-MP	28.6	25.5±4.8
U1-SN	92.7	103.4±5.5
L1-MP	75.2	96.3±5.4
U1-L1	155.5	129.1±7.1
UL-E	-0.4	- 1.6±1.5mm
LL-E	2.6	- 0.2±1.9mm



治疗前CBCT



- 上下前牙区牙槽基骨薄
- 牙槽骨缺损（骨开裂骨开窗）



问题列表

Skeletal

- 骨性I类
- 均角骨面型

Dental

- 安氏II²类
- III°深覆，spee曲线陡
- 12过小牙，Bolton比不调
- 14、24、34、44已拔除
- 上前牙直立,下前牙舌倾
- 18、28、38、48阻生

Soft tissue

- 颏唇沟深

Periodontal

- 牙槽骨缺损
- 严重根形暴露

TMJ

(-)

Upper Airway

(-)

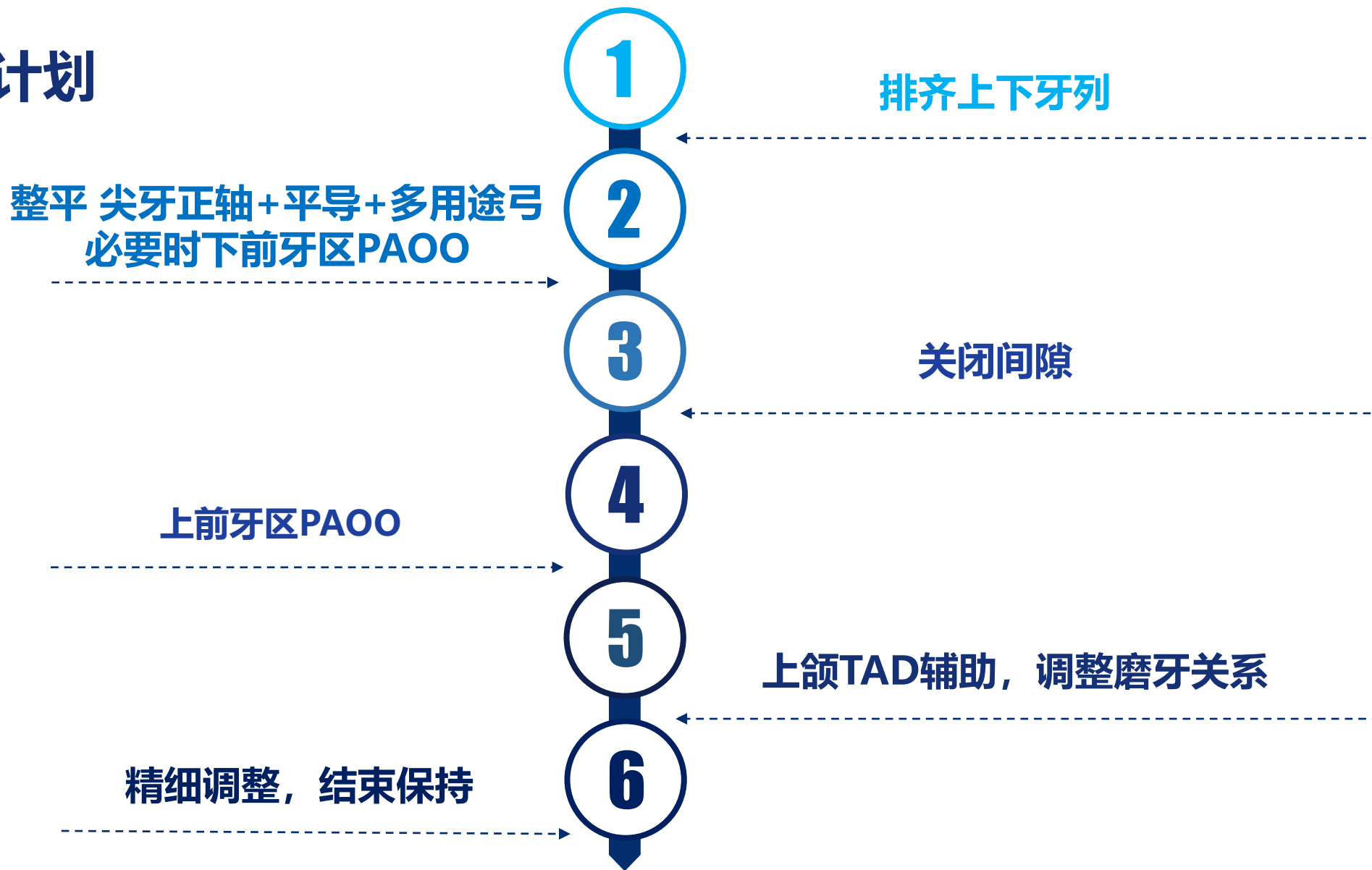

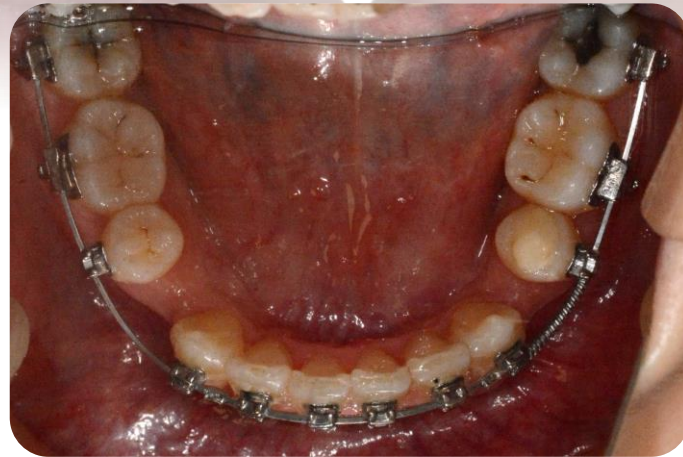
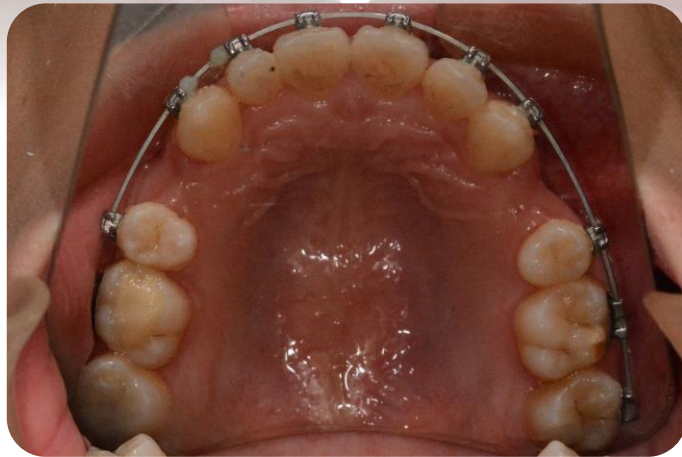
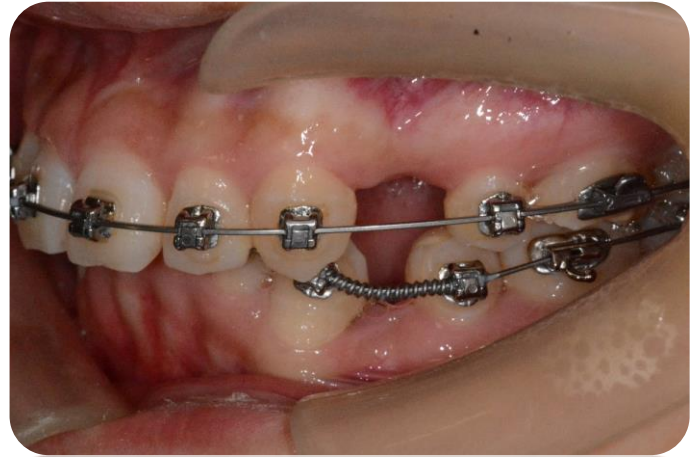
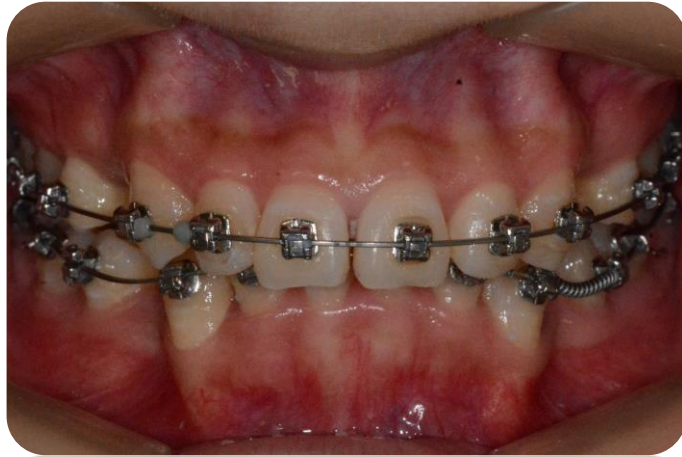
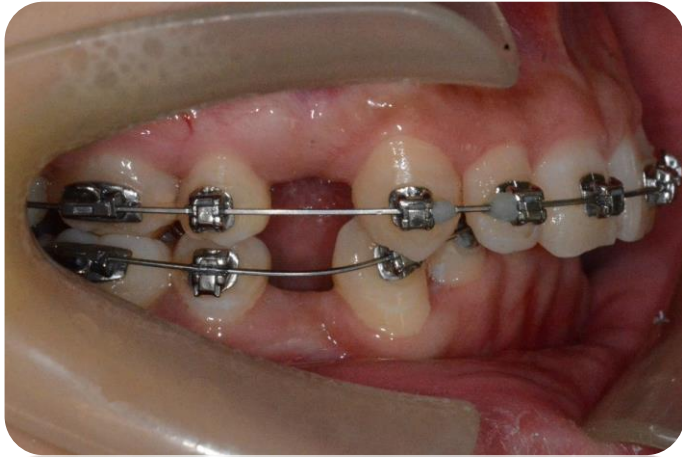
治疗目标

- 基本维持侧貌
- 排齐上下牙列
- 建立前牙正常覆 覆盖
- 建立后牙中性关系

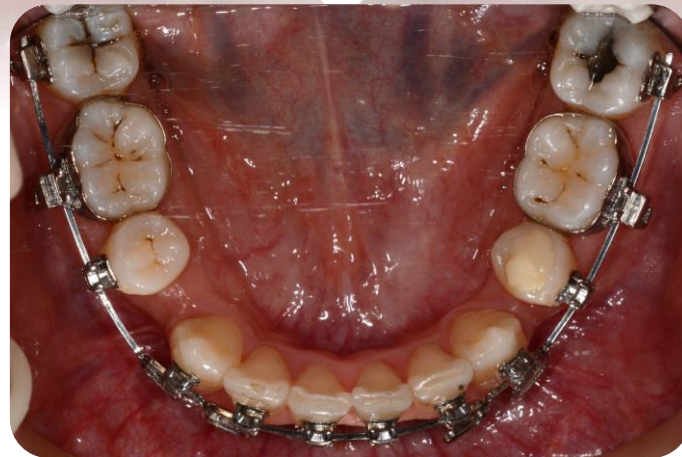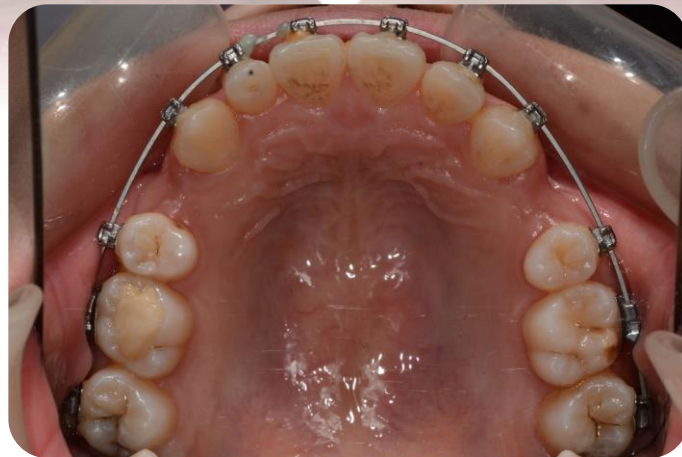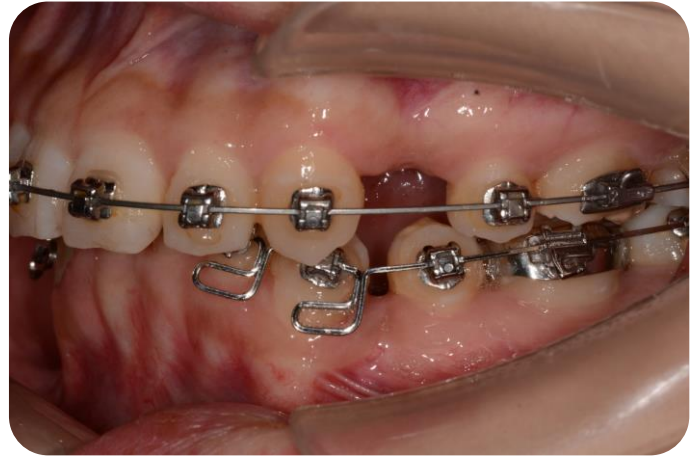
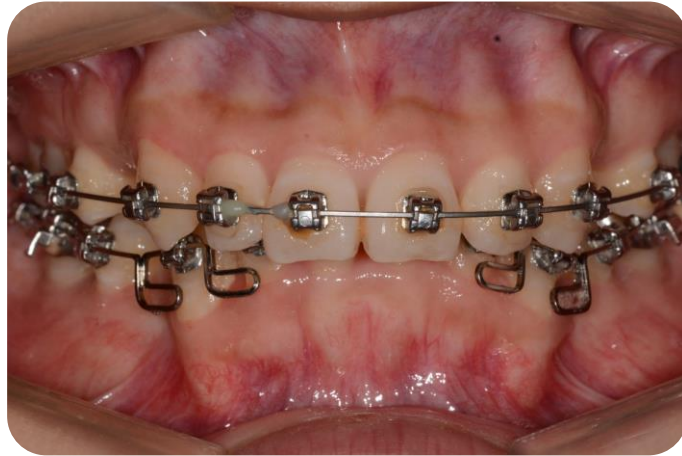
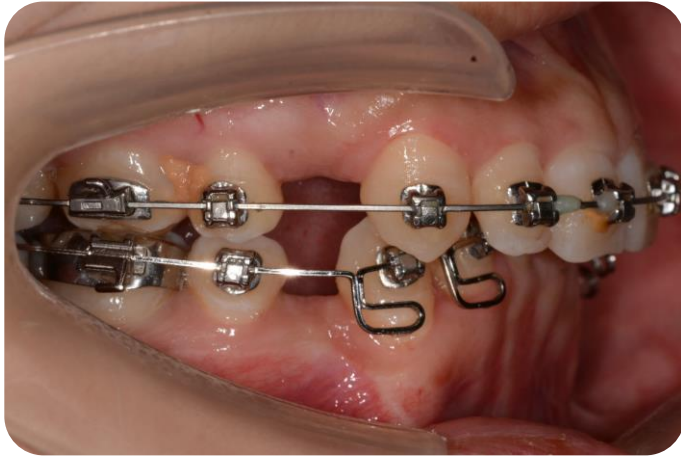


治疗计划

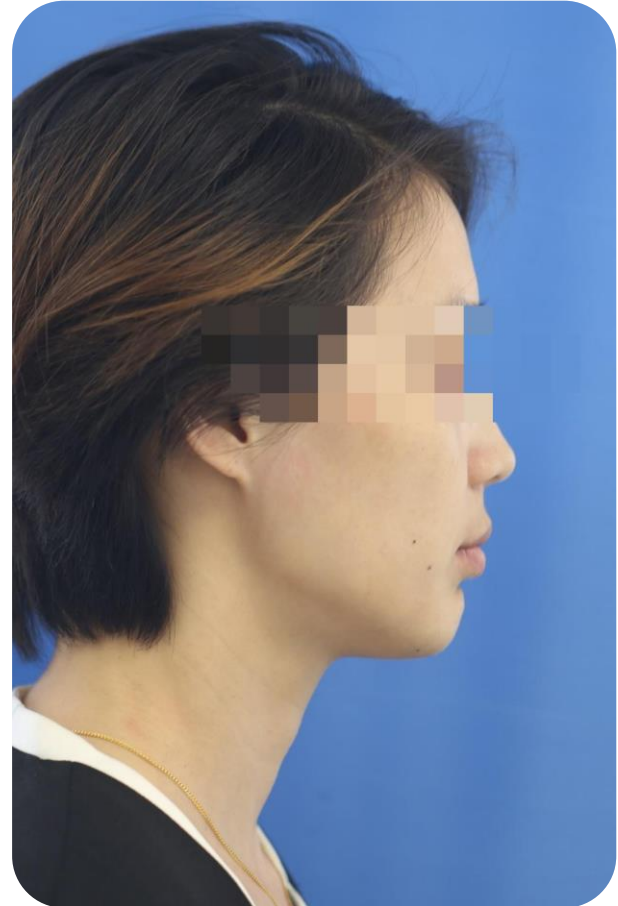
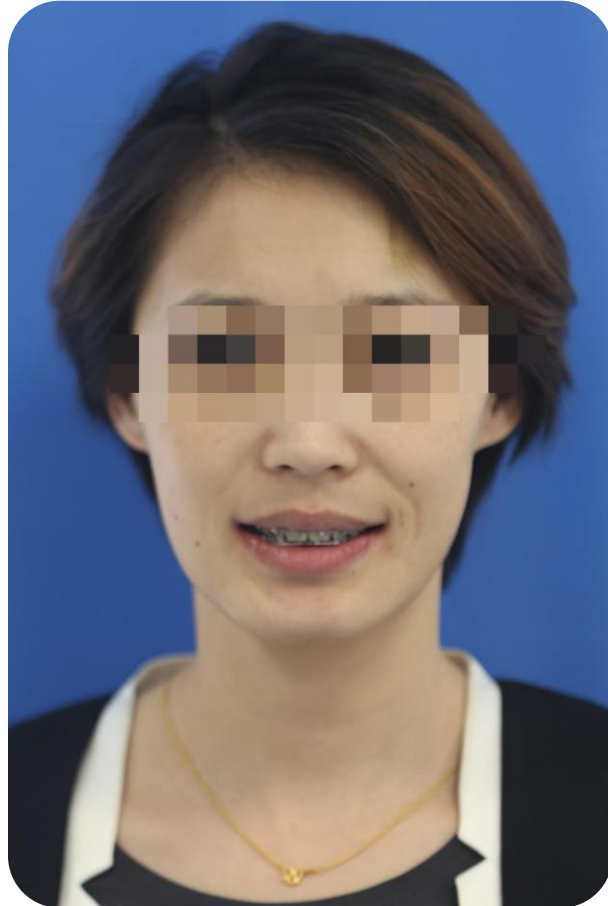
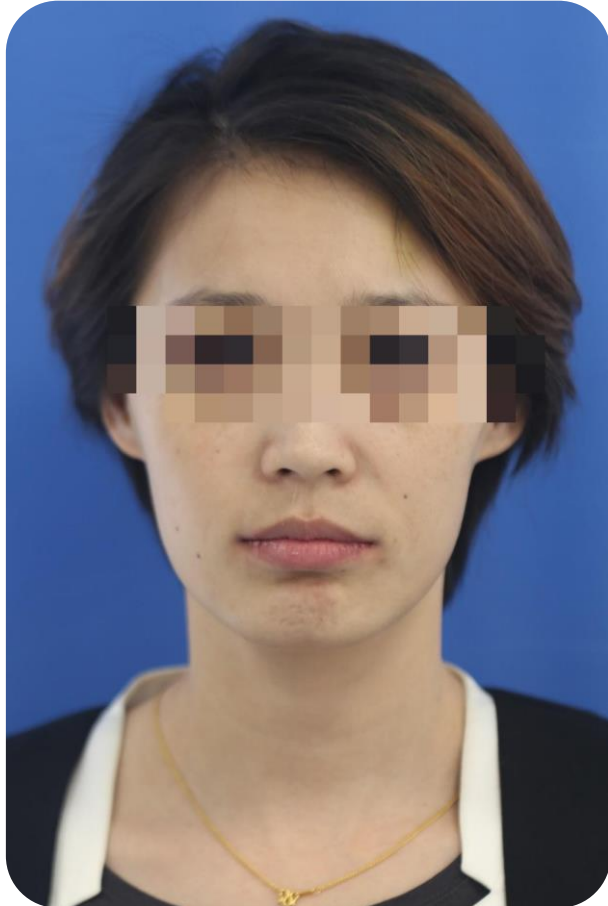


5 months

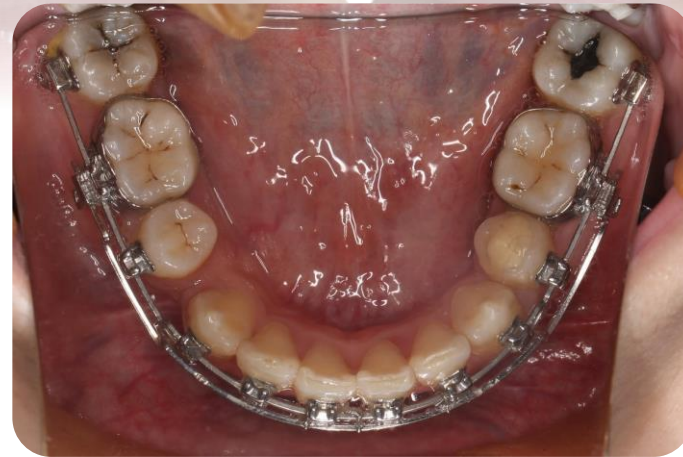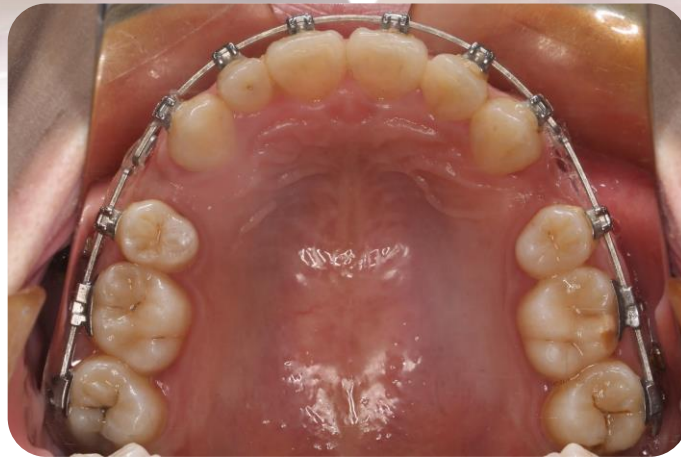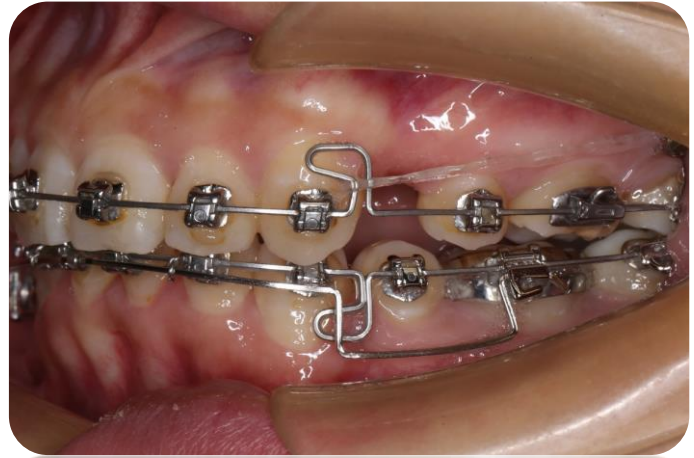
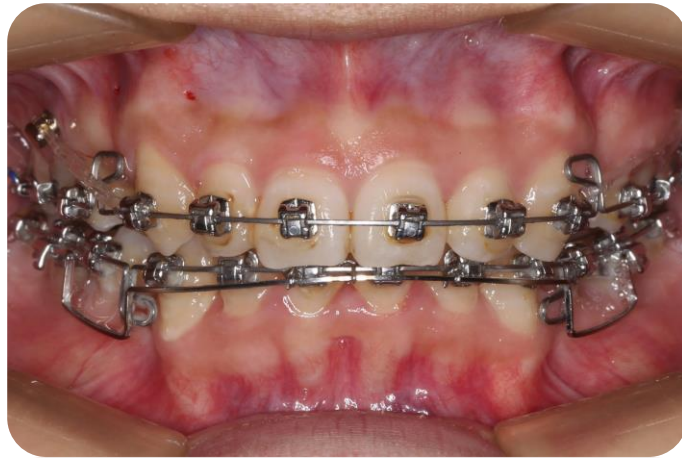
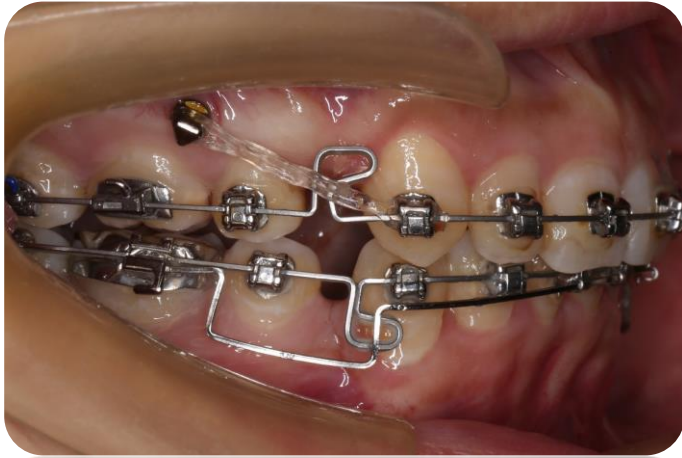


8 months

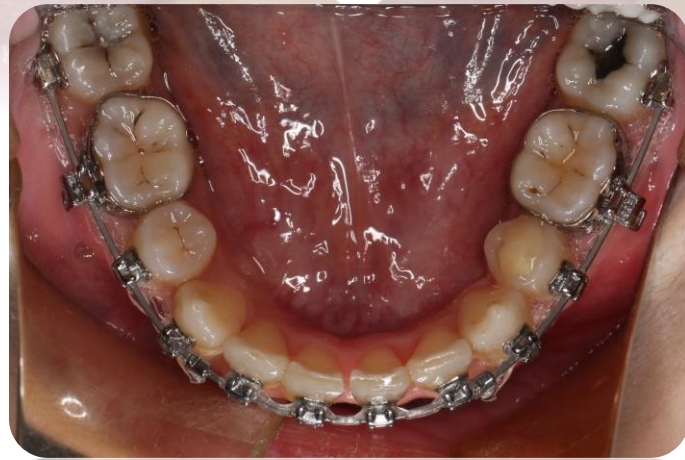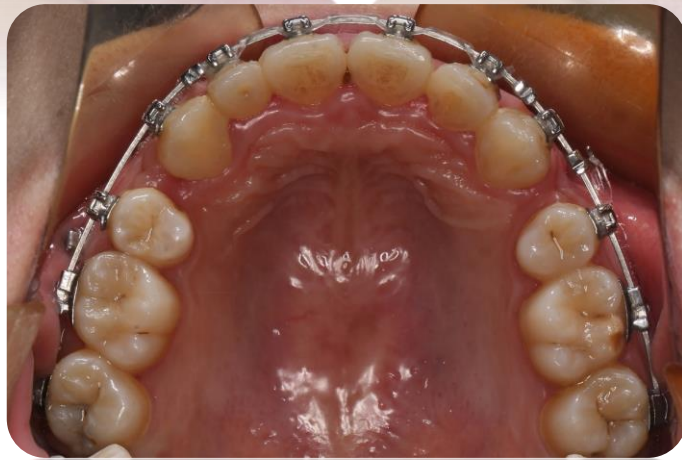
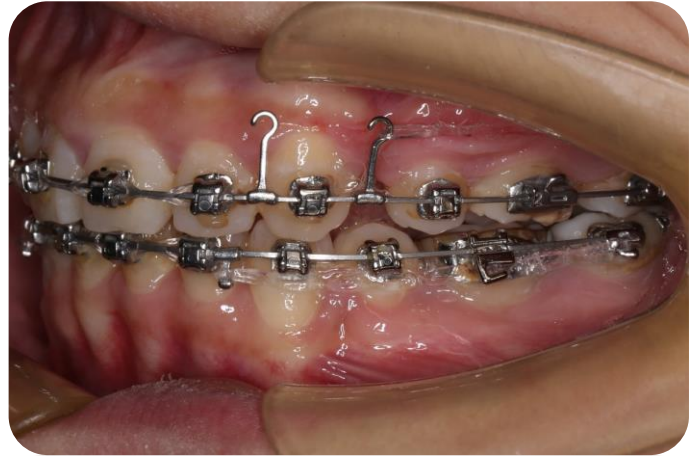

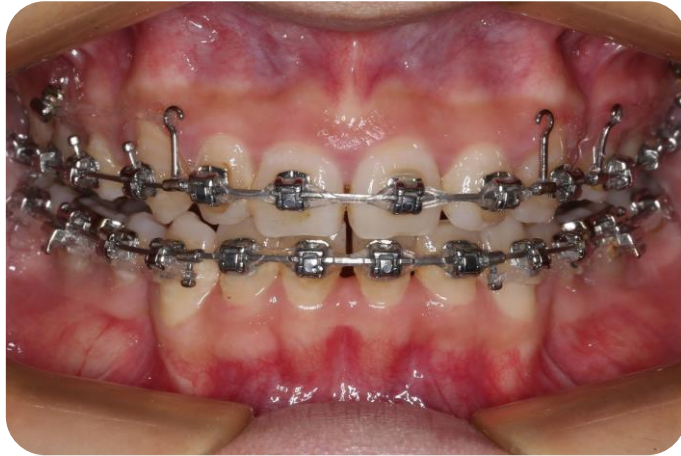
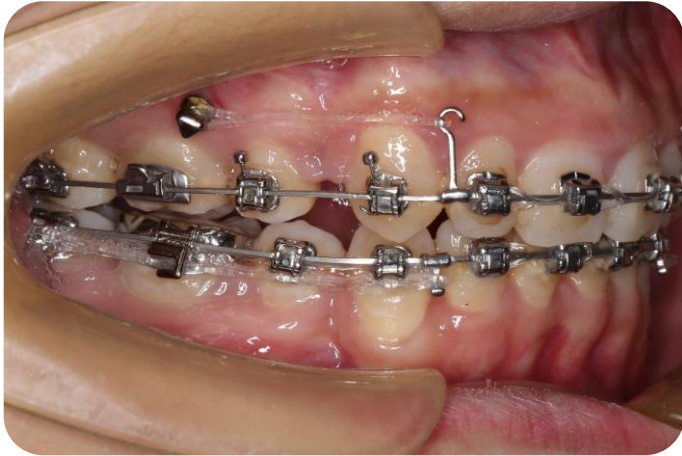18 months

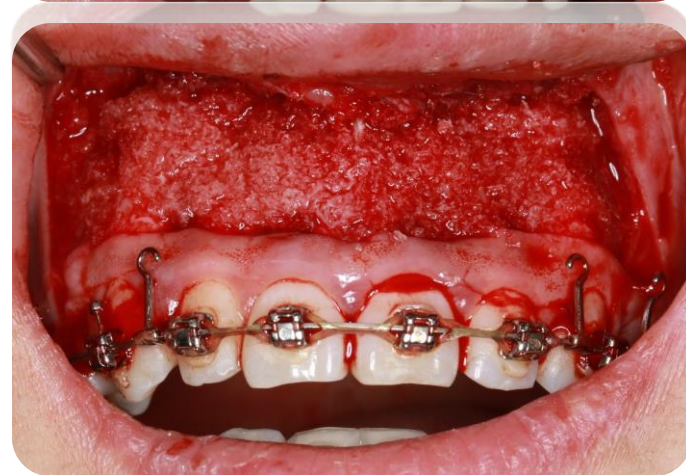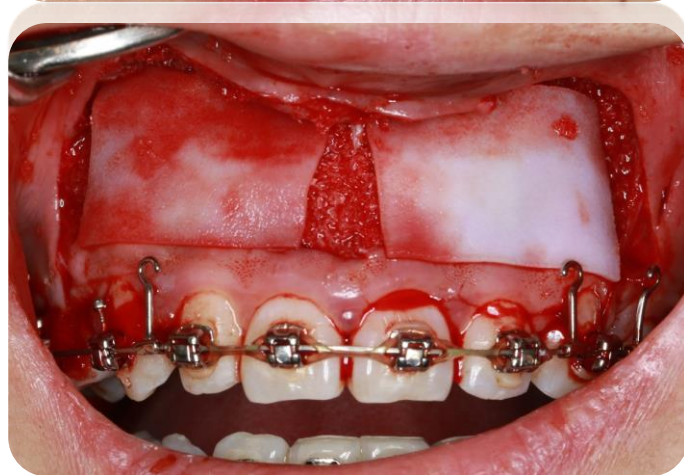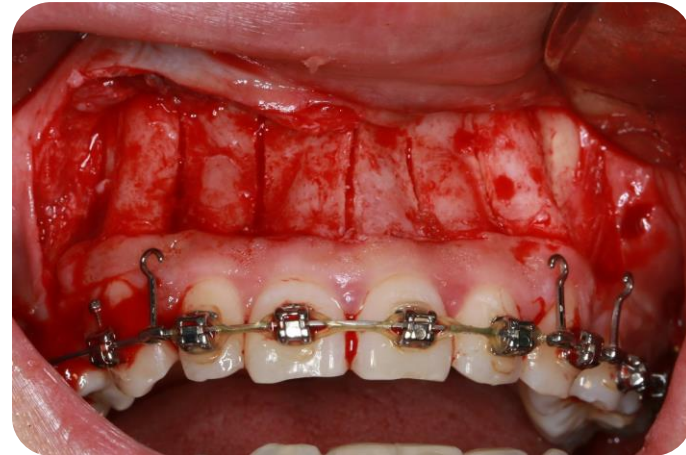


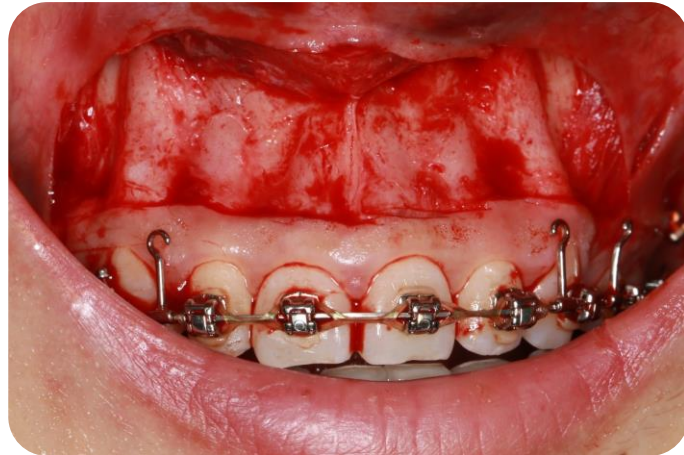

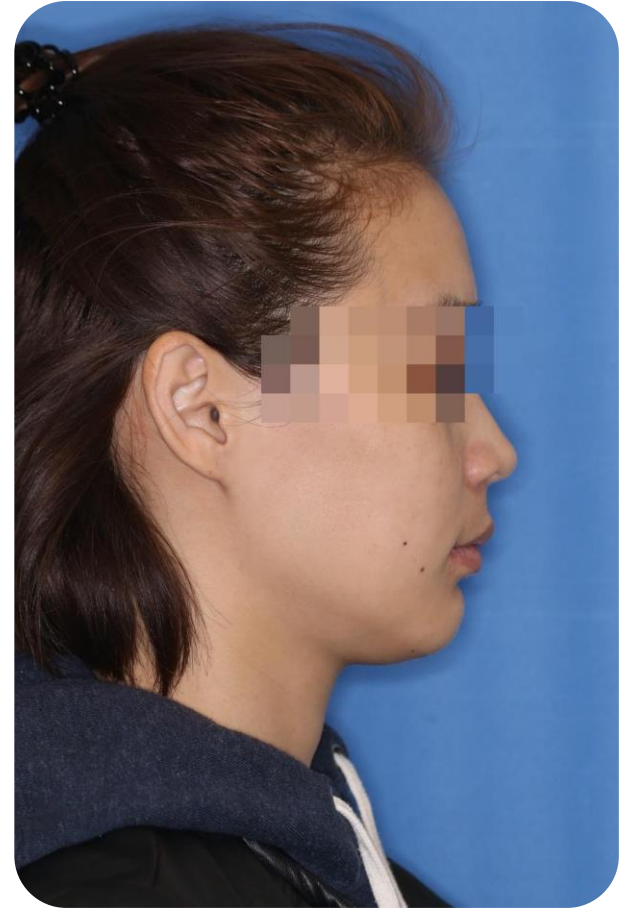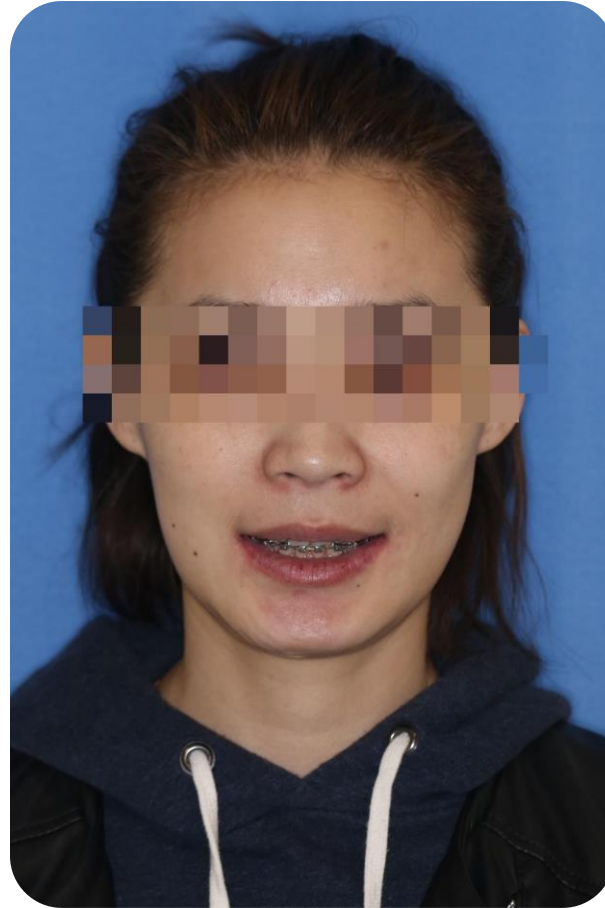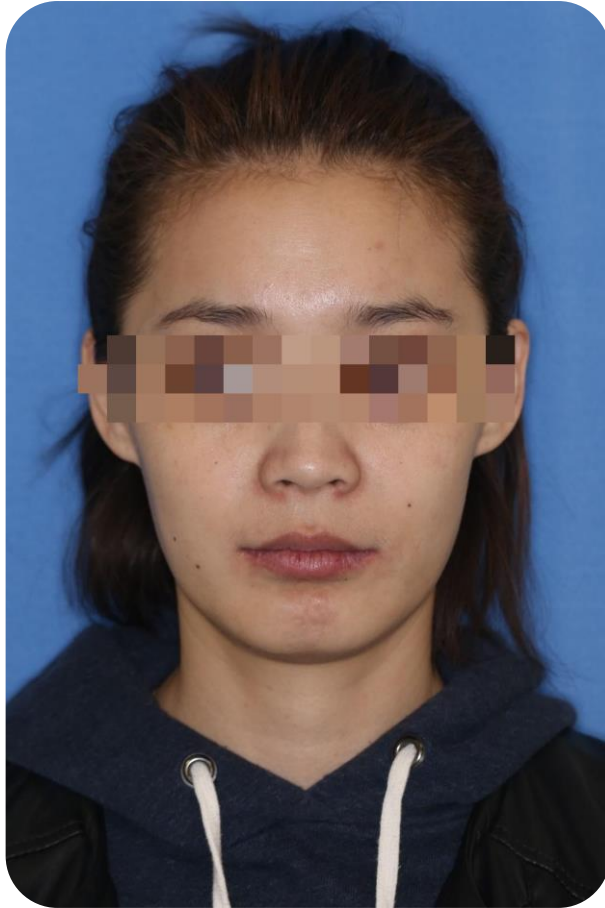18 months



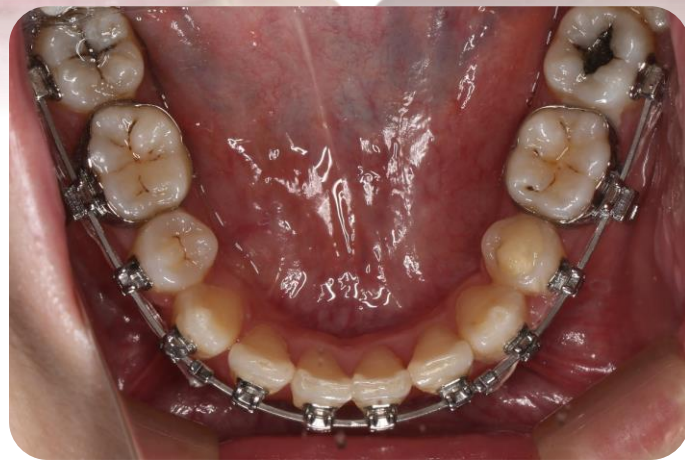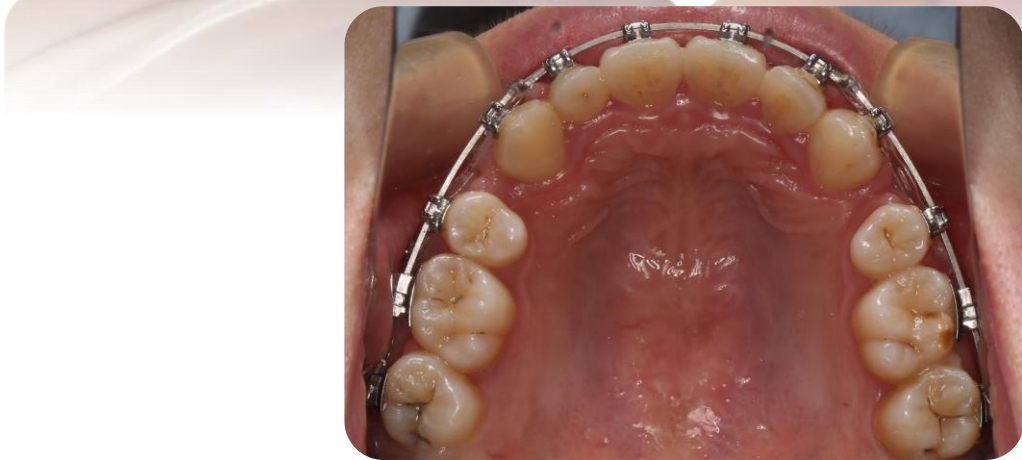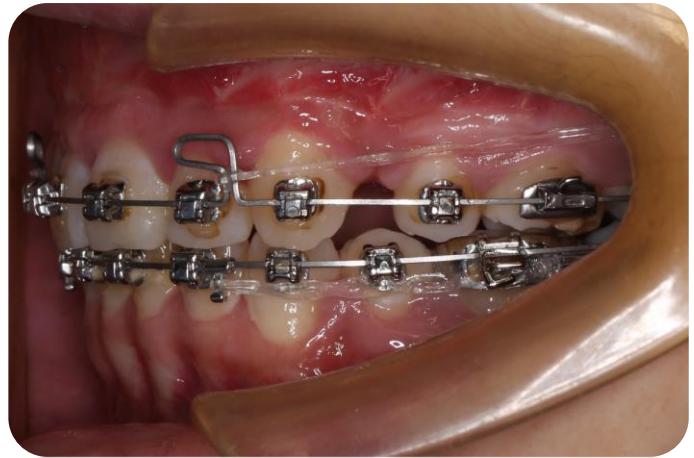
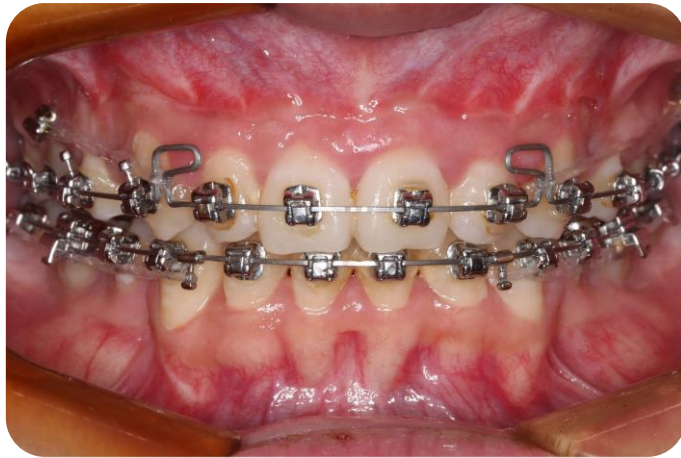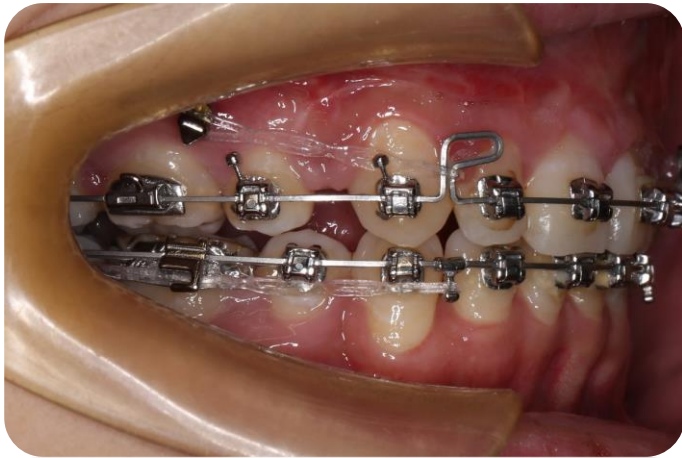
23 months



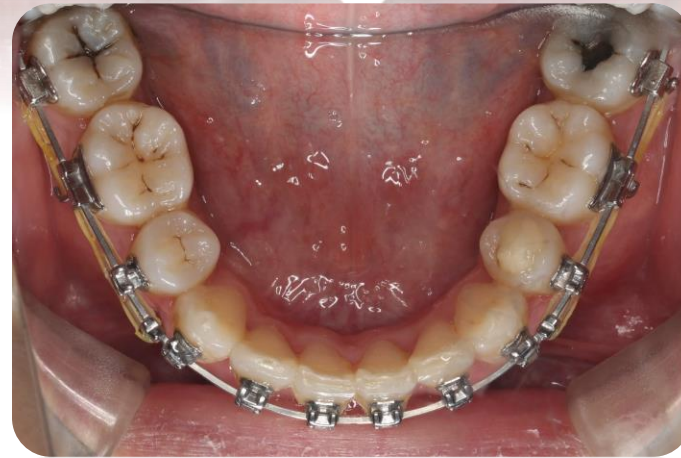
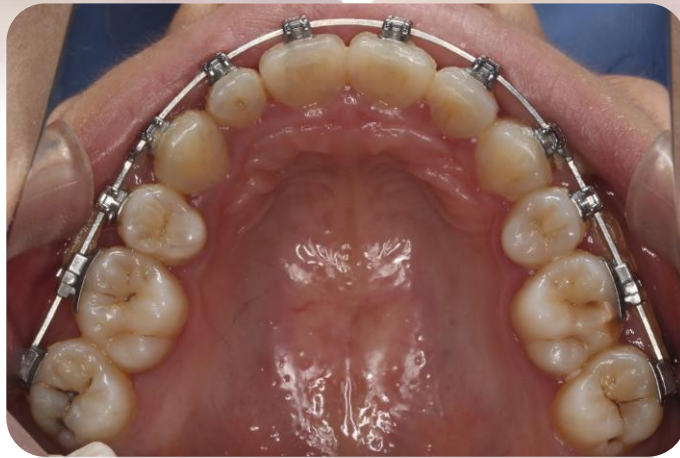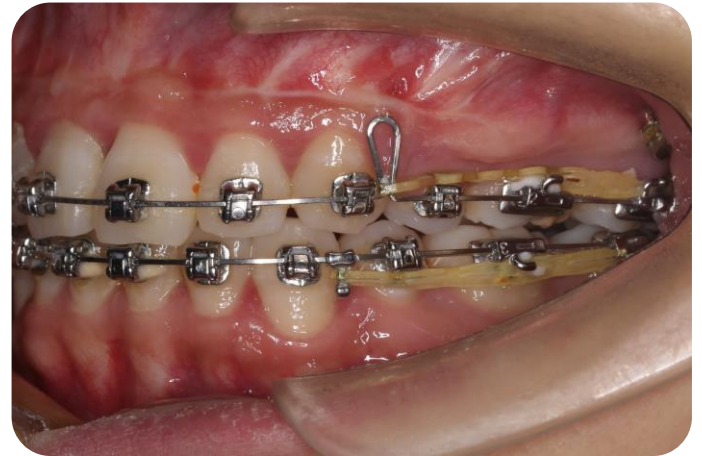
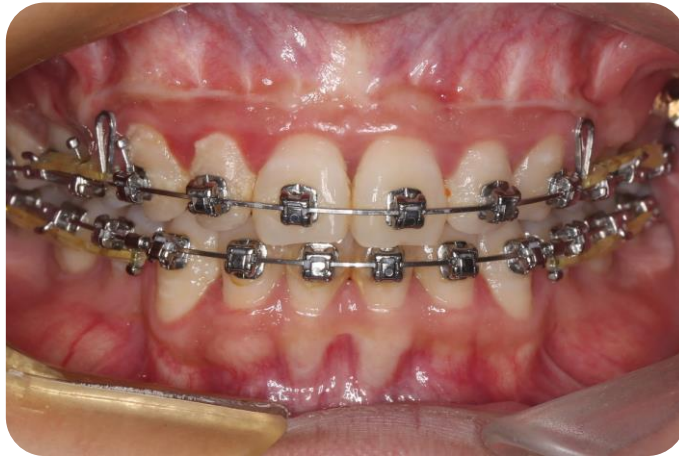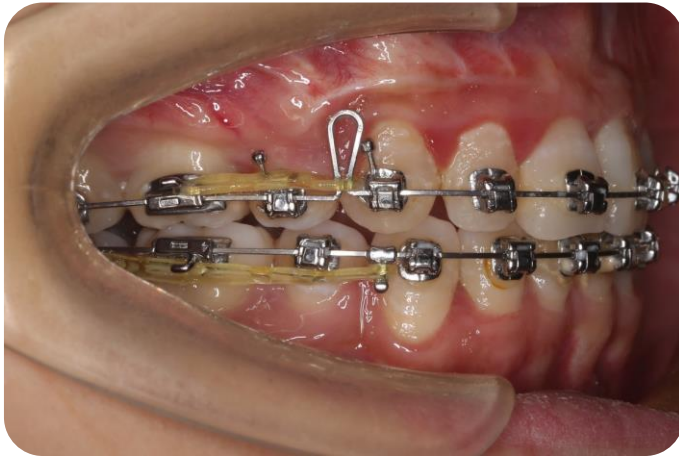
23 months



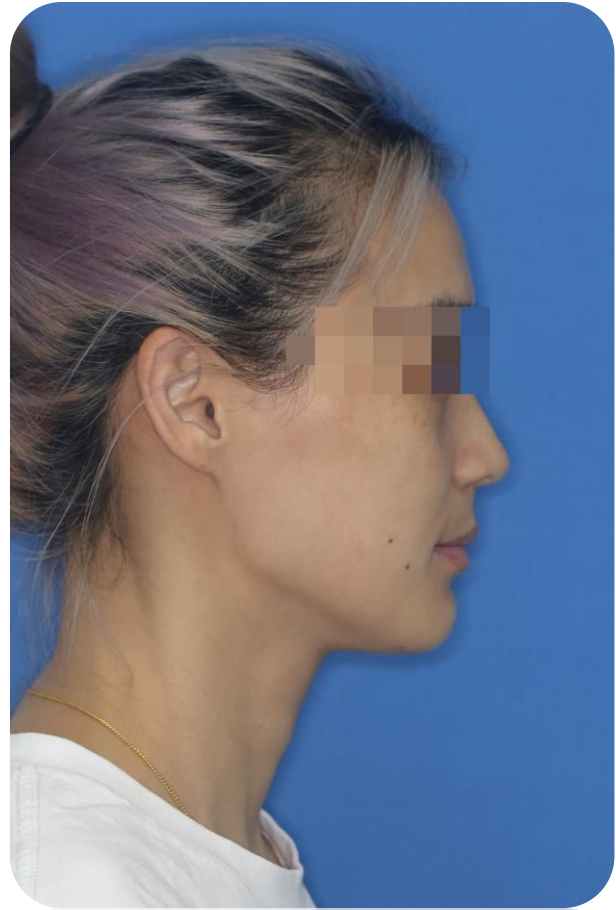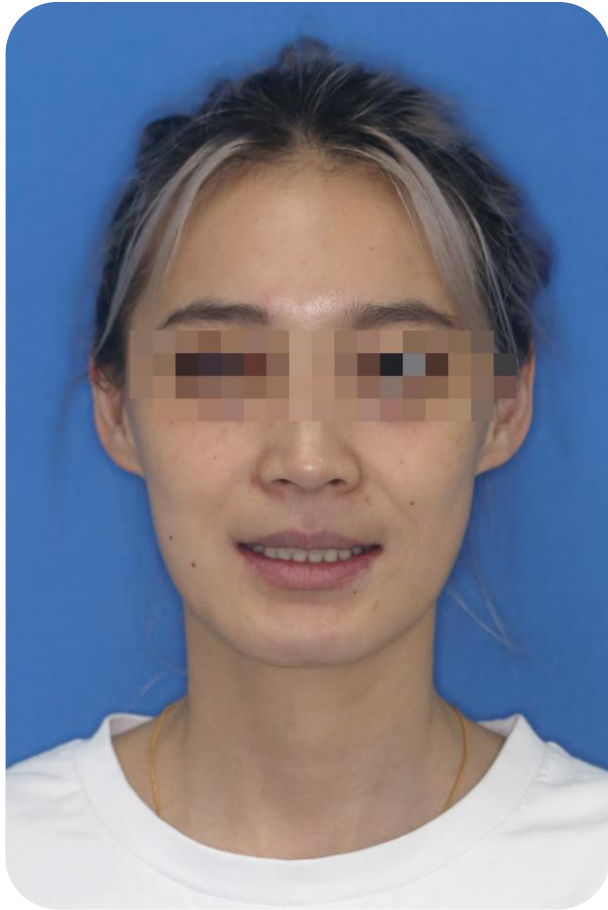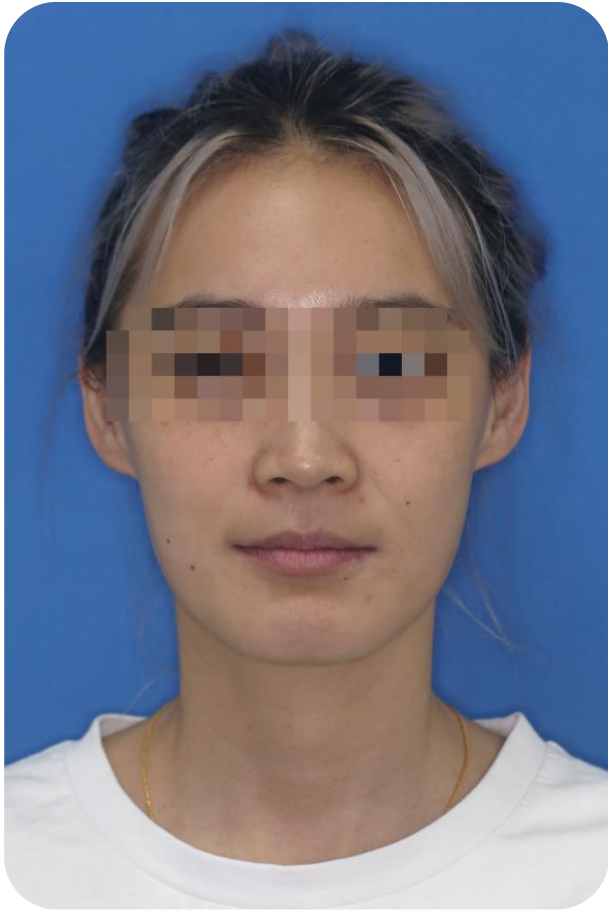23 months



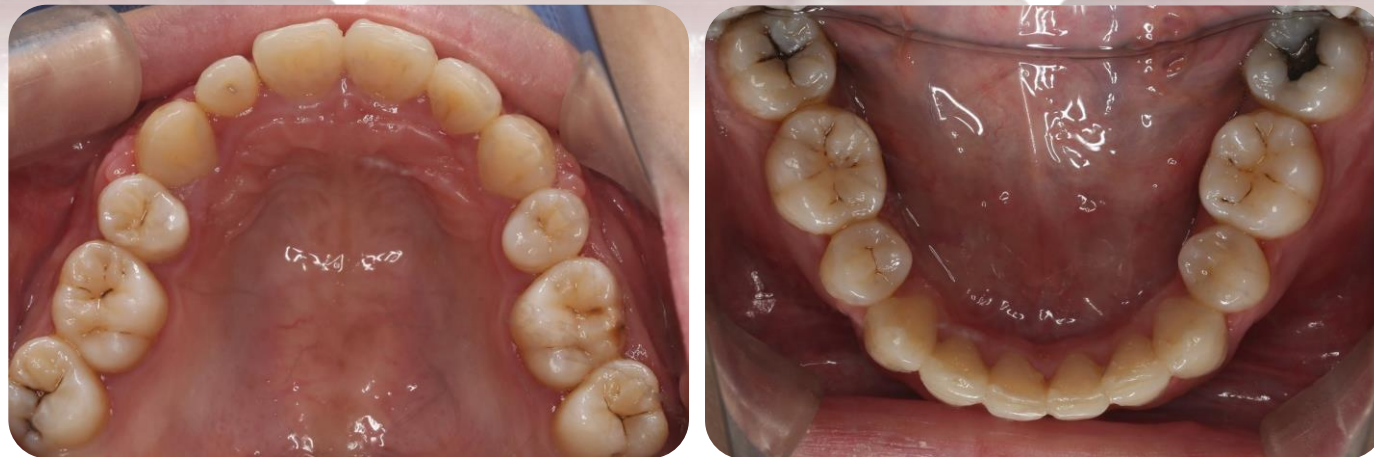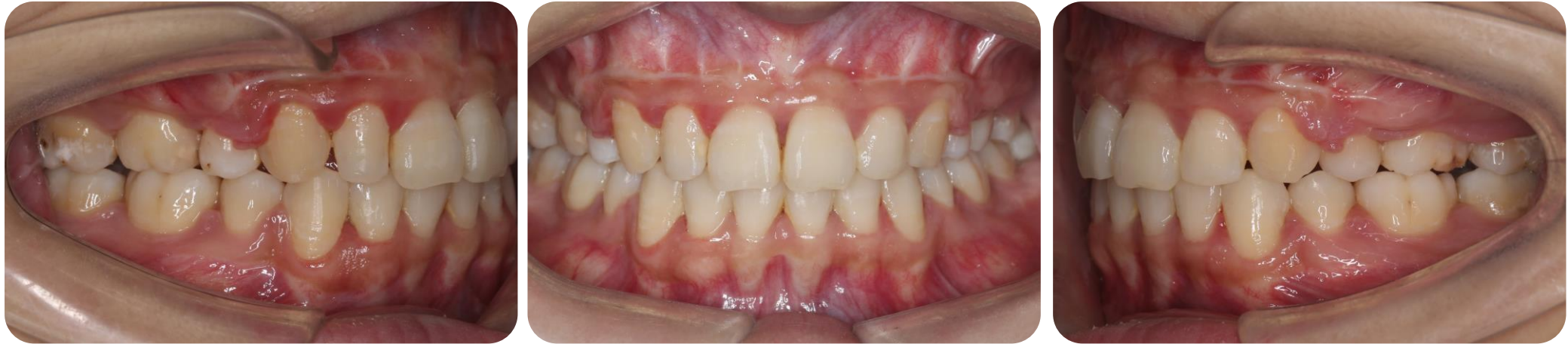25 months



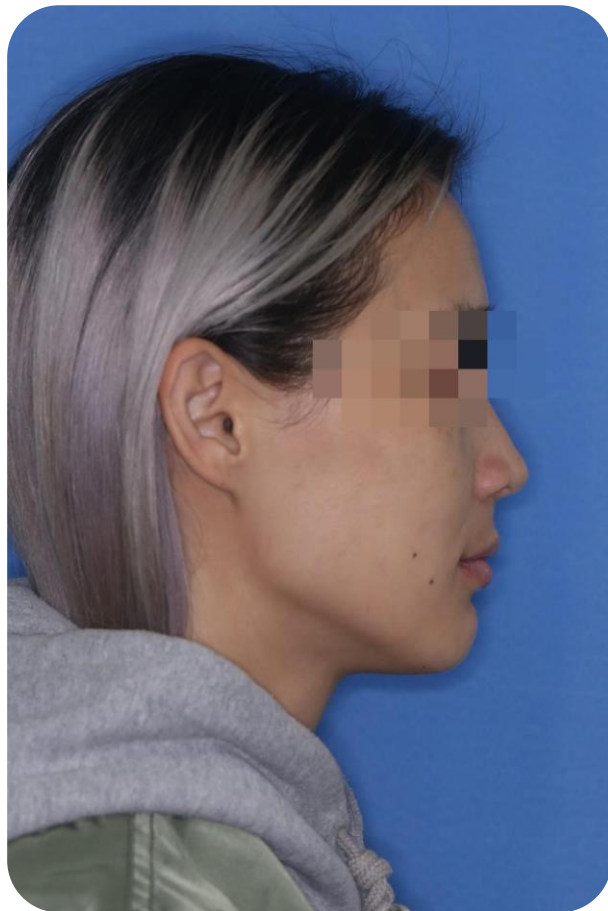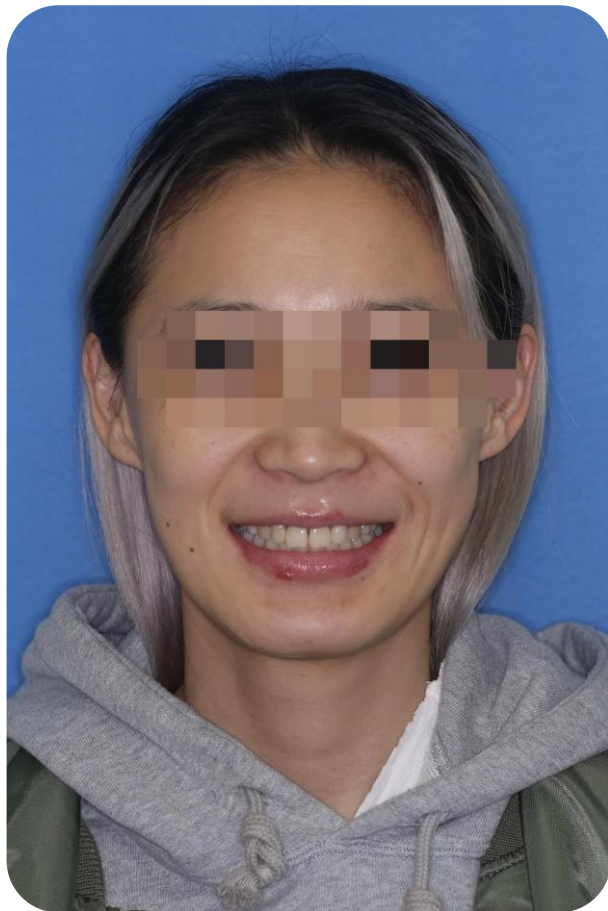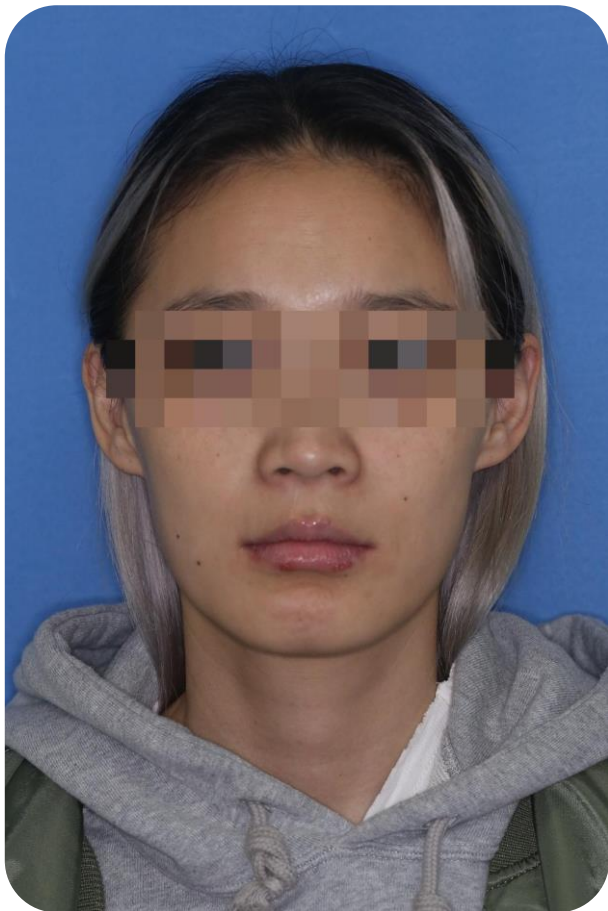34 months



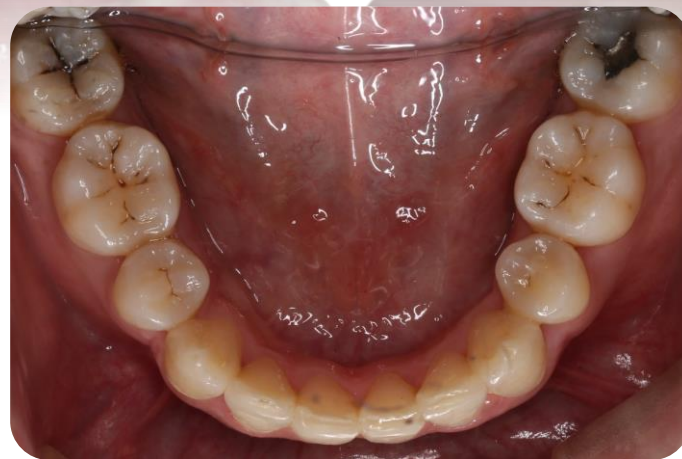
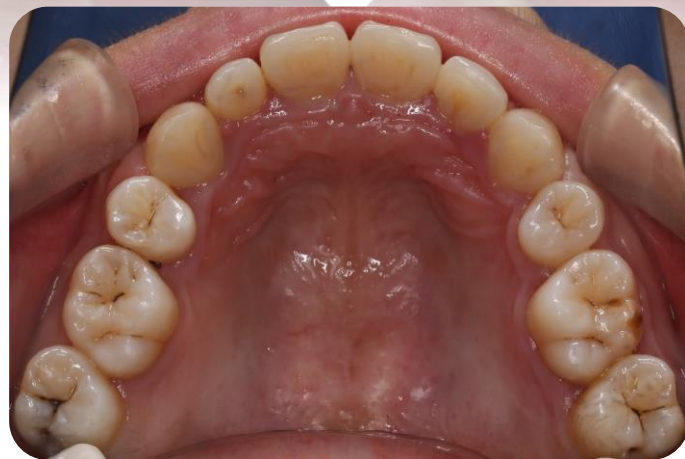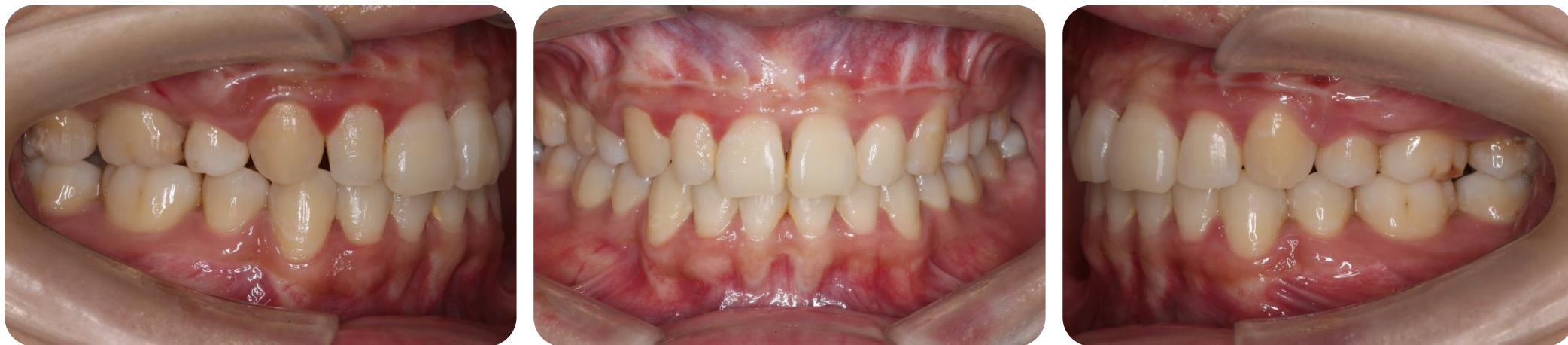36 months



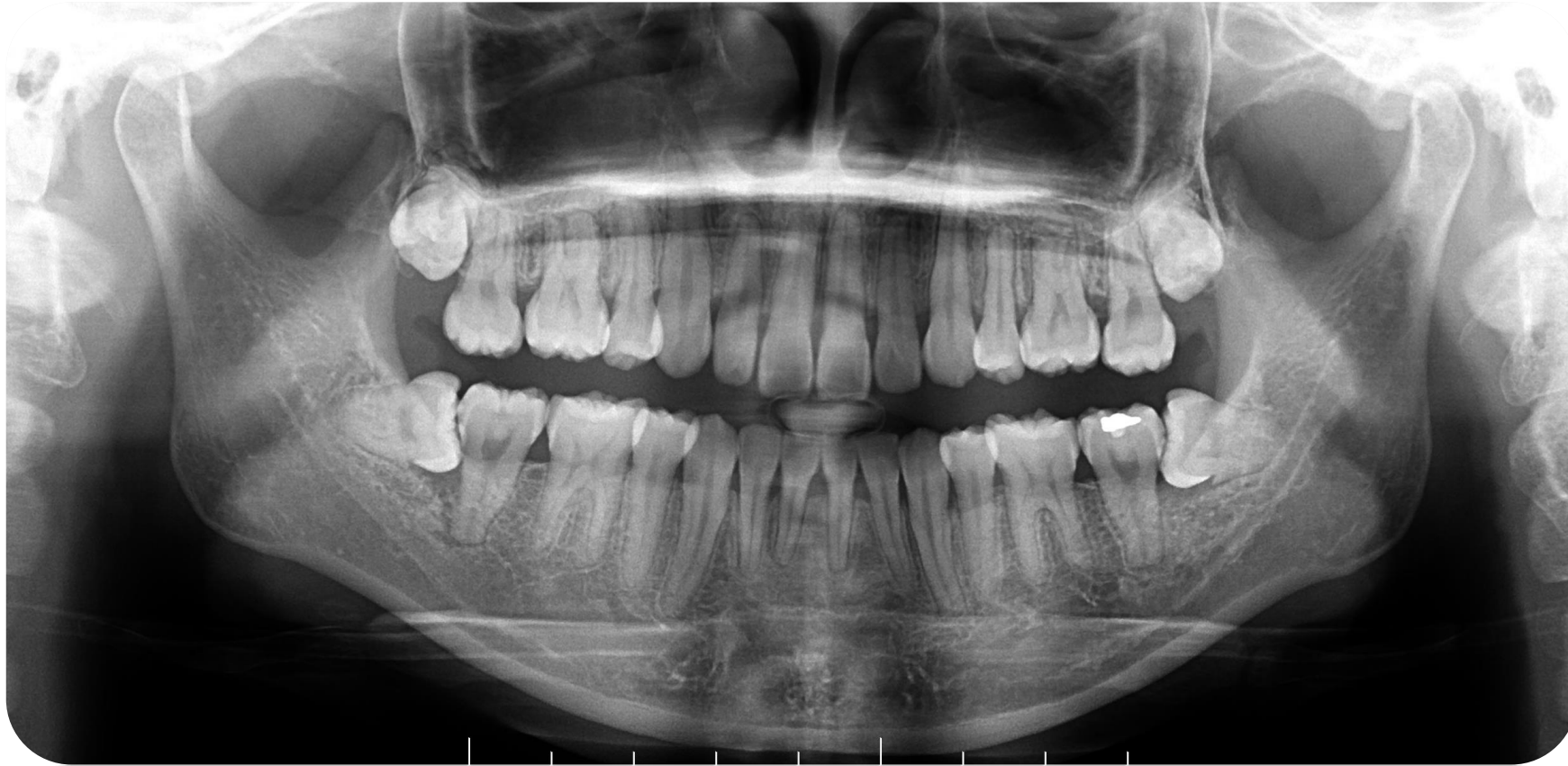36 months

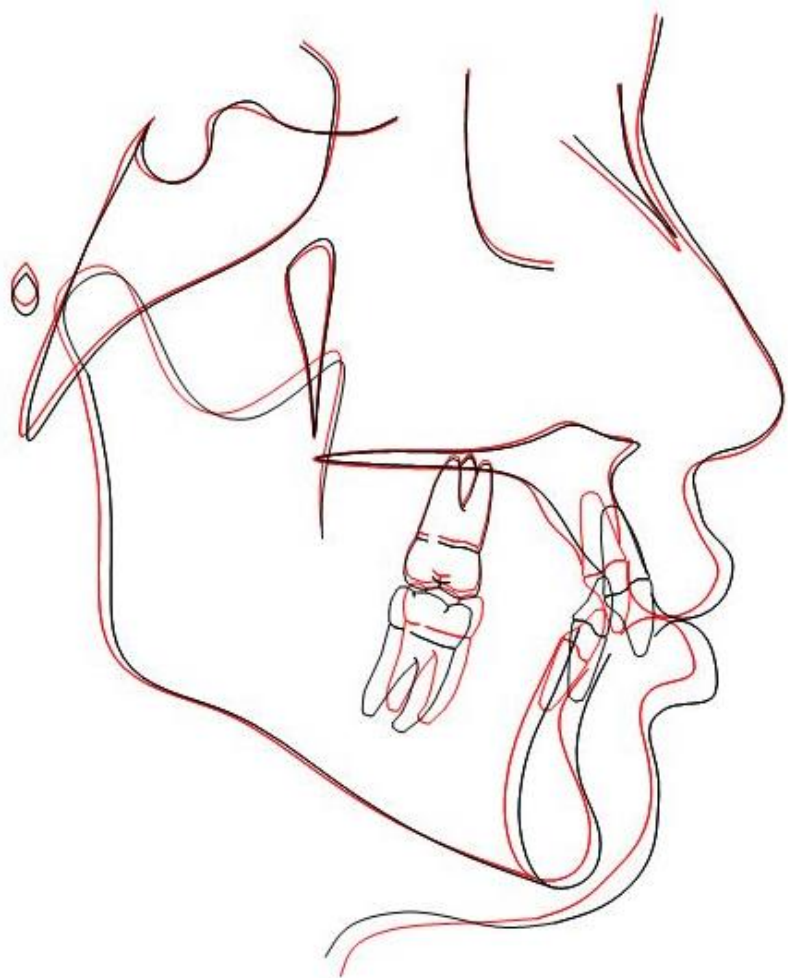


随访 3个月

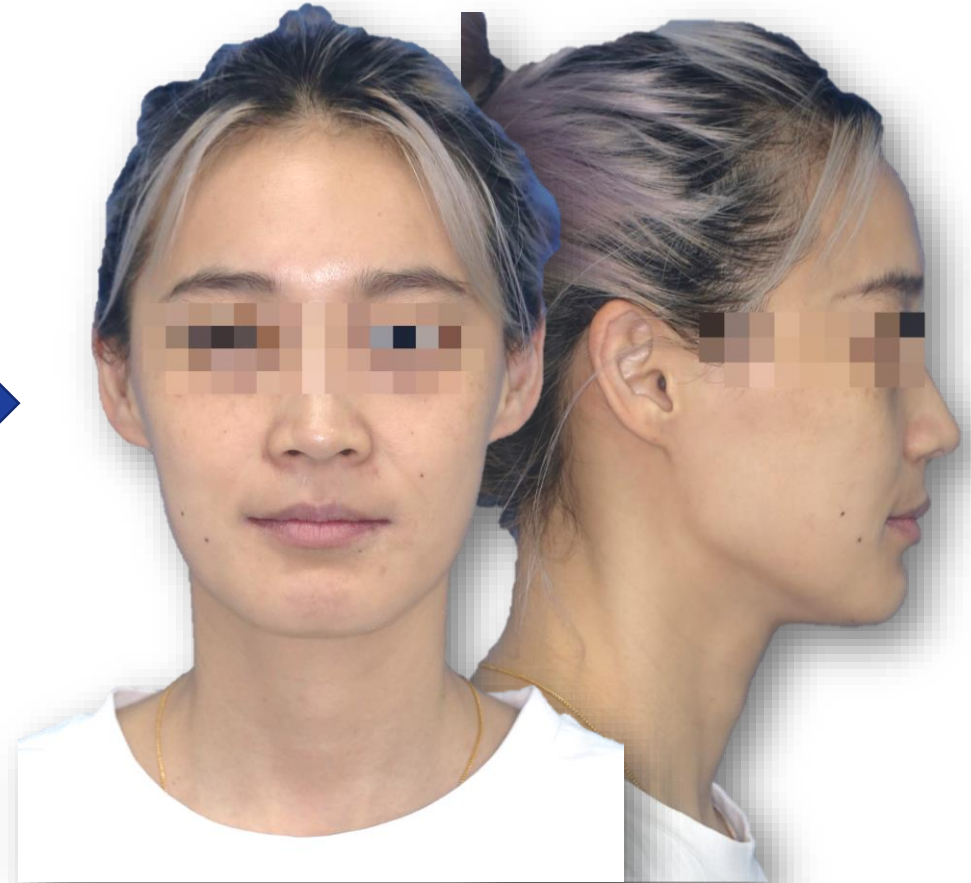
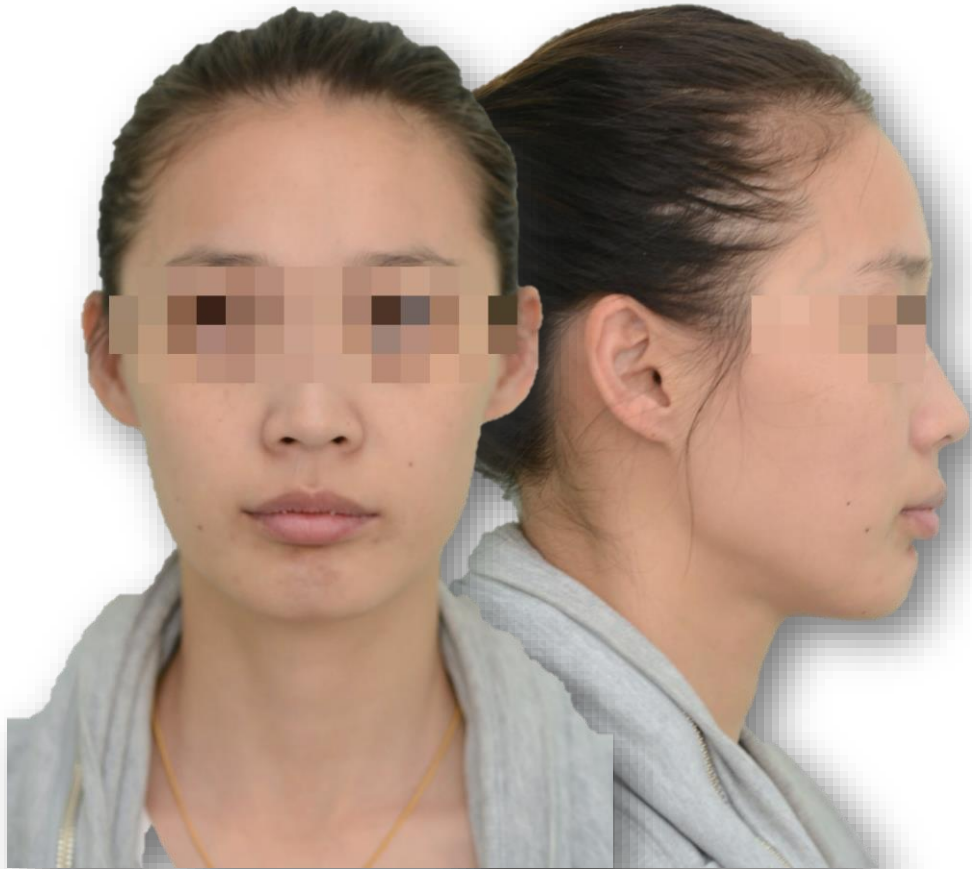
随访 3个月



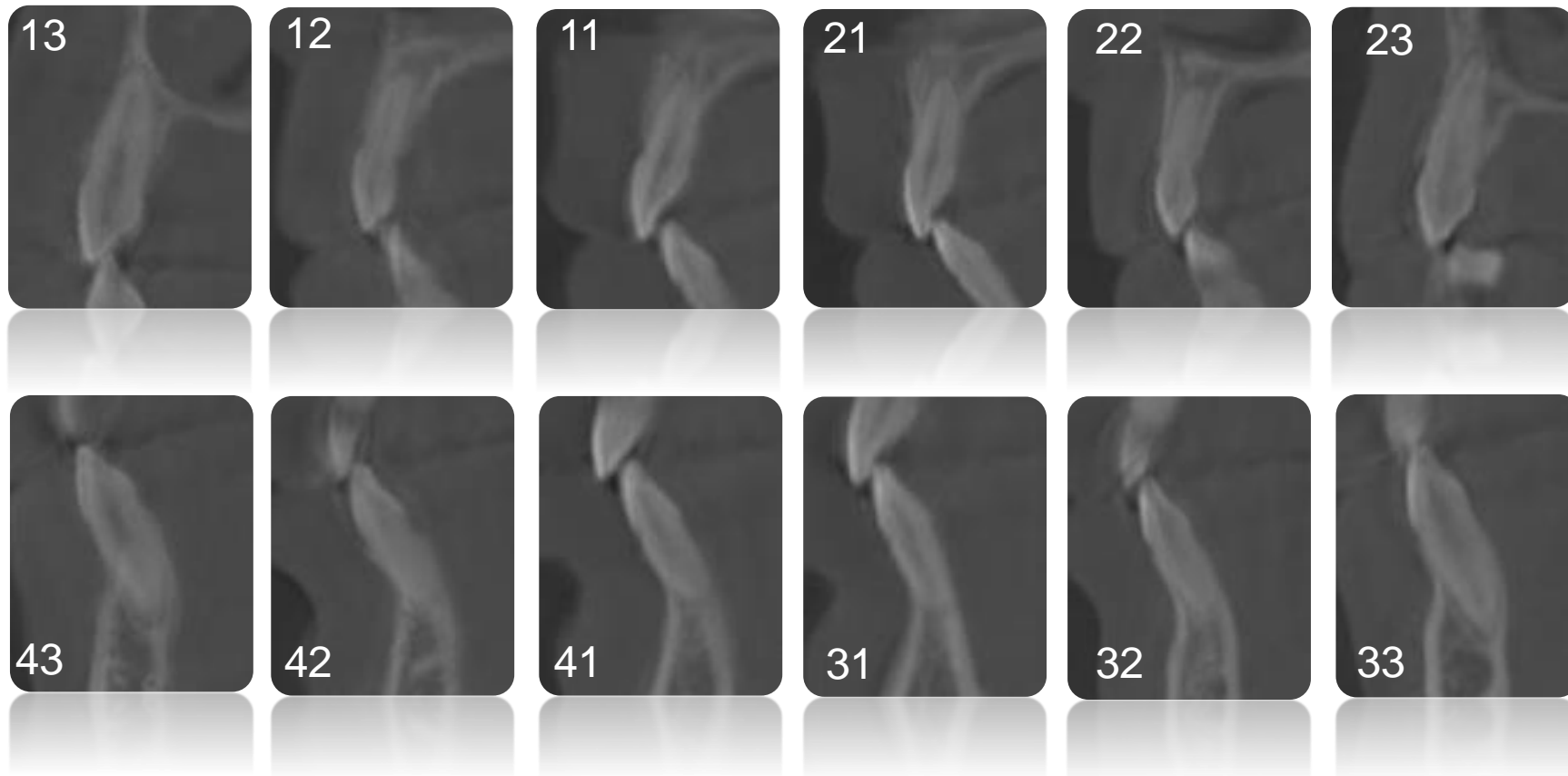


测量项目	治疗前	治疗后	正常值 (LIU)
SNA	80.2	80.4	83.1±2.7
SNB	77.8	77.9	80.3±2.6
ANB	2.4	2.5	2.7±1.8
MP-SN	36.7	36.3	32.6±6.9
FH-MP	28.6	27.8	25.5±4.8
U1-SN	92.7	93.8	103.4±5.5
L1-MP	75.2	93	96.3±5.4
U1-L1	155.5	136.9	129.1±7.1
UL-E	-0.4	-1.4	- 1.6±1.5mm
LL-E	2.6	-0.3	- 0.2±1.9mm



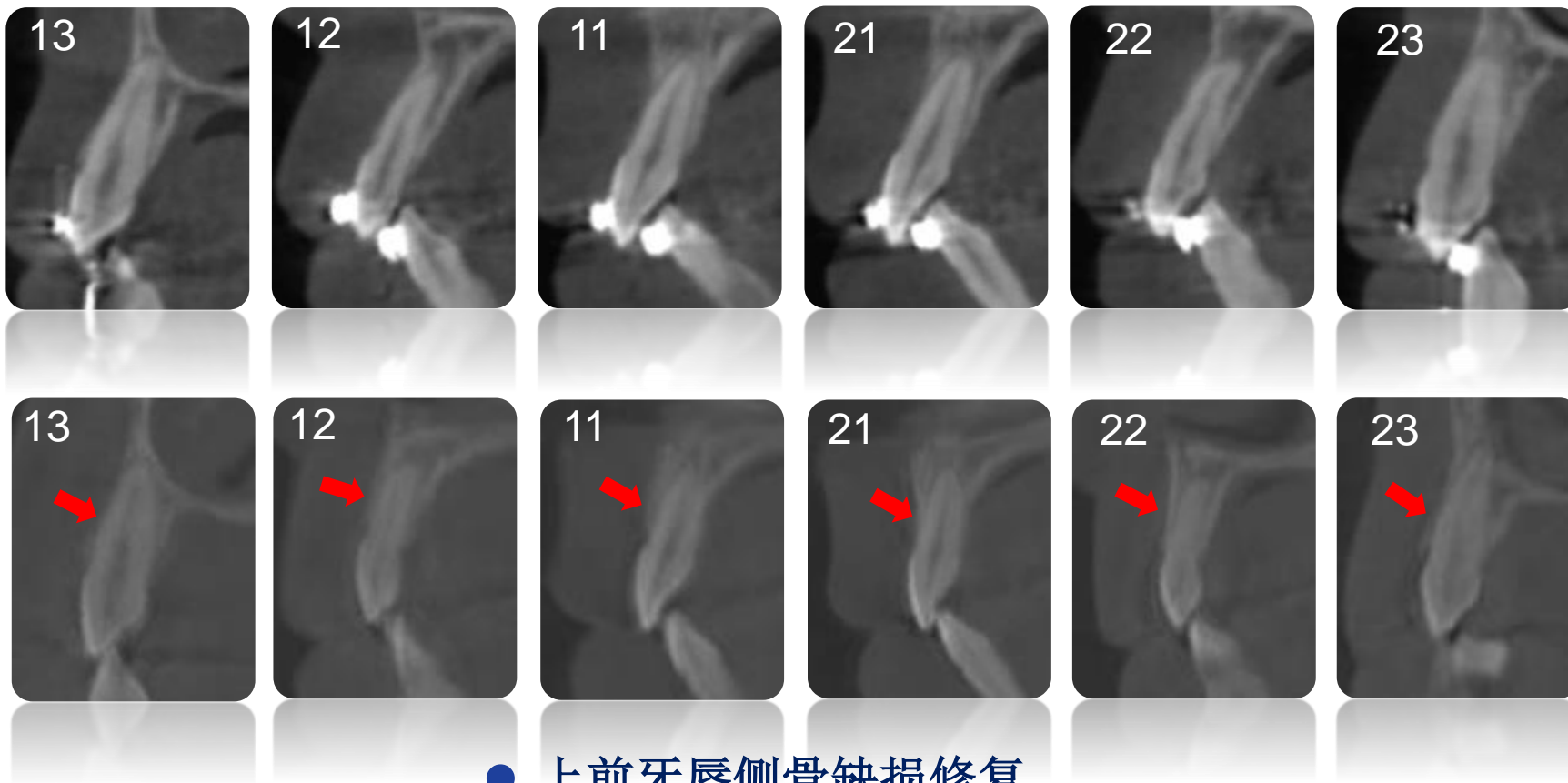


治疗后CBCT





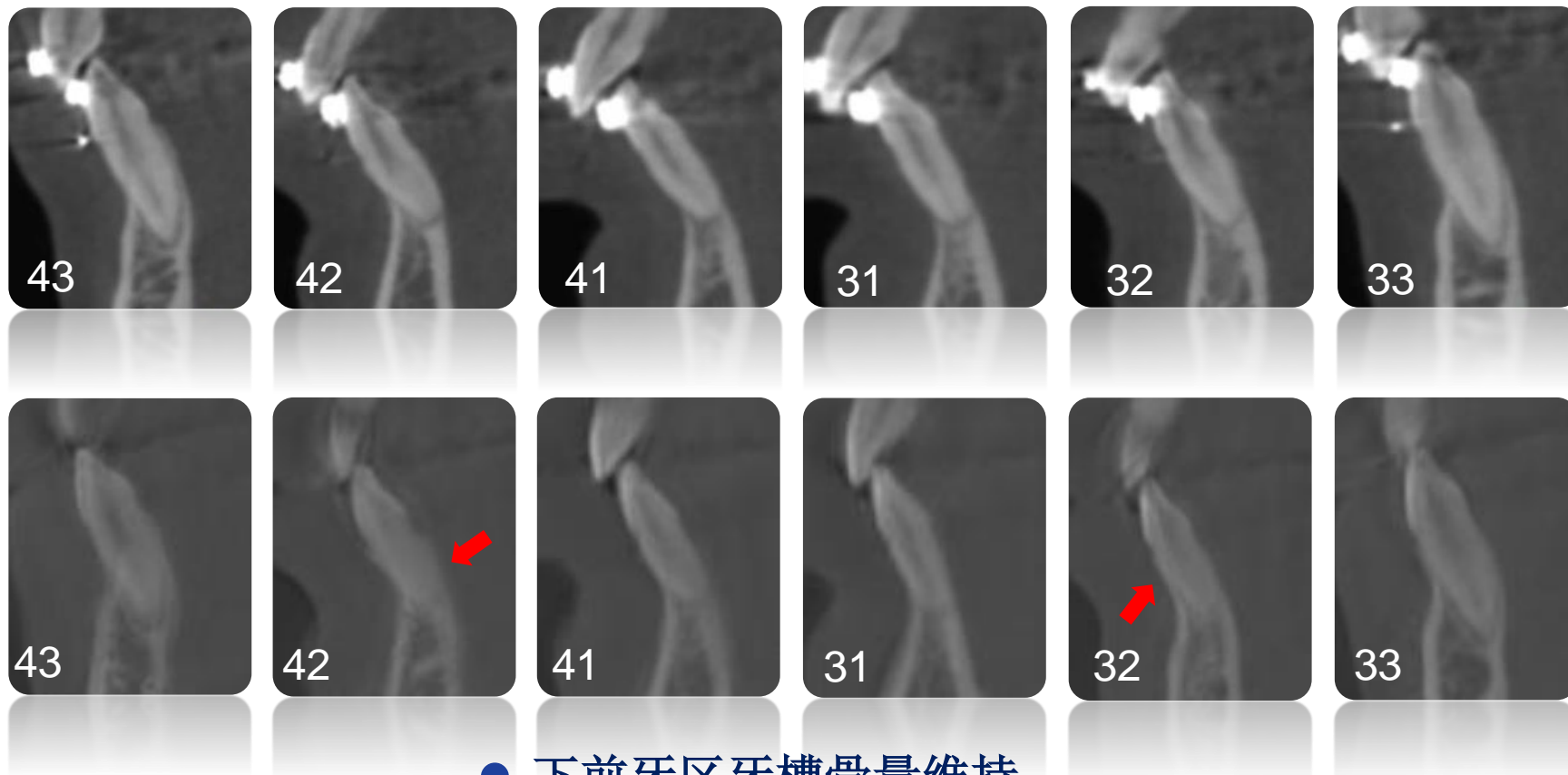
CBCT前后对比



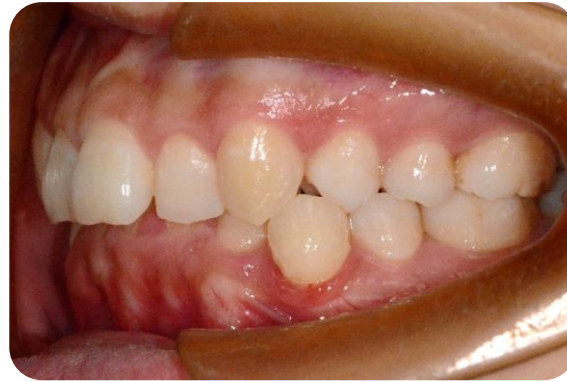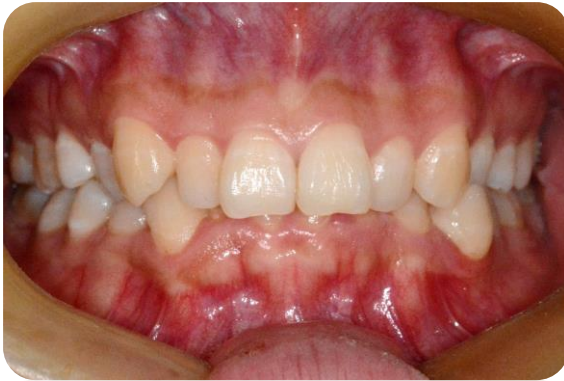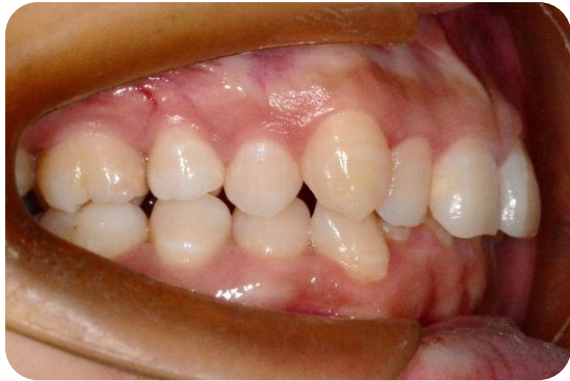- 上前牙唇侧骨缺损修复
- 有利于维持上唇丰满度



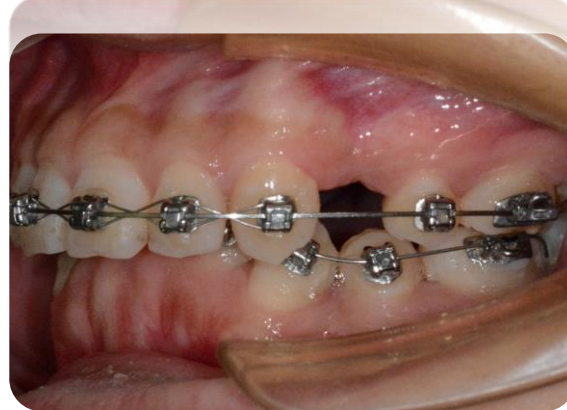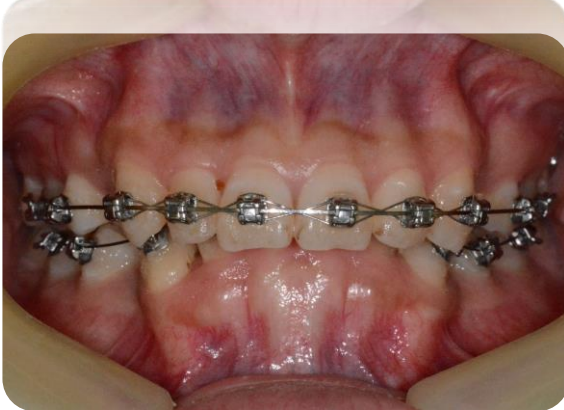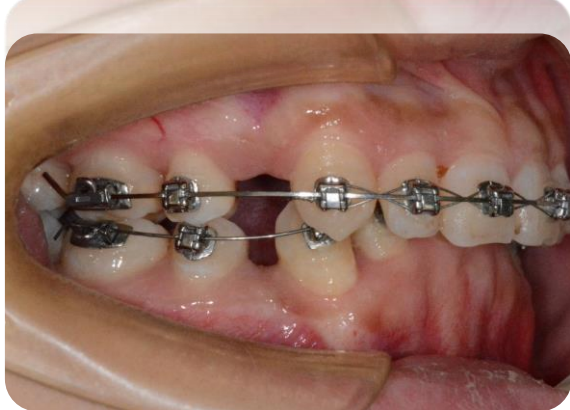CBCT前后对比



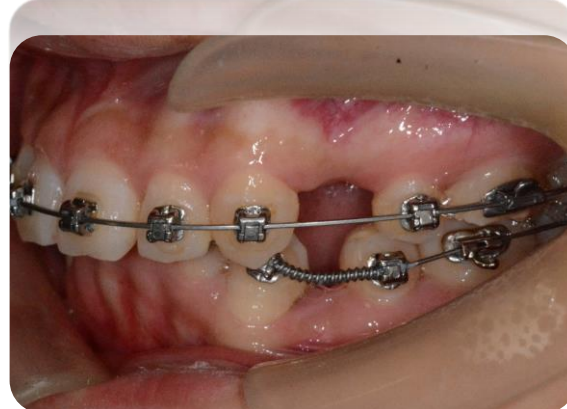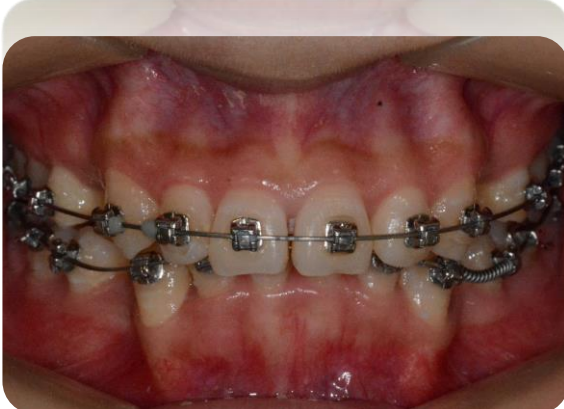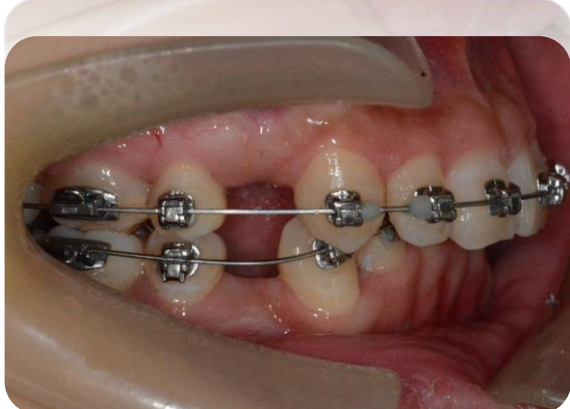
- 下前牙区牙槽骨量维持
- 局部根骨关系改善



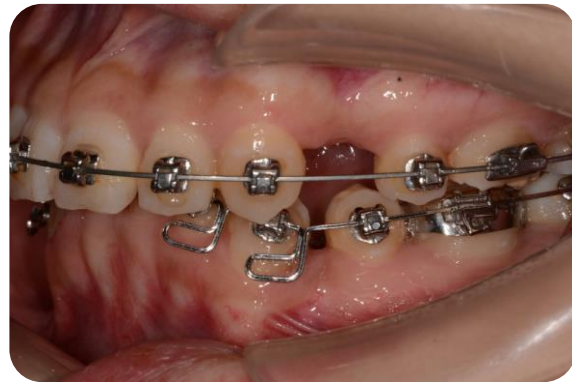
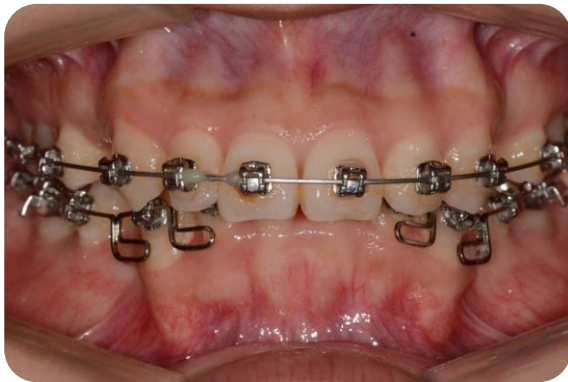
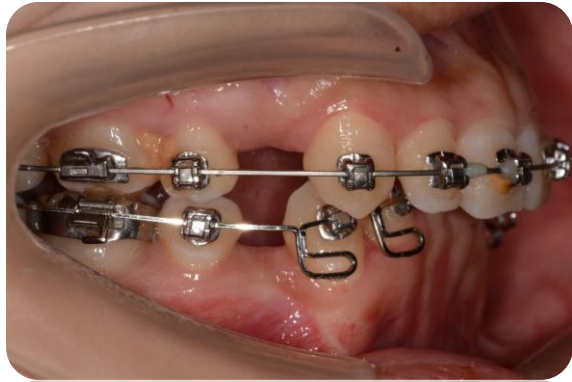
-12 months



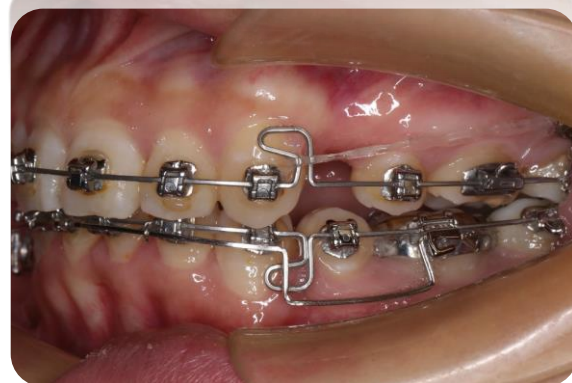
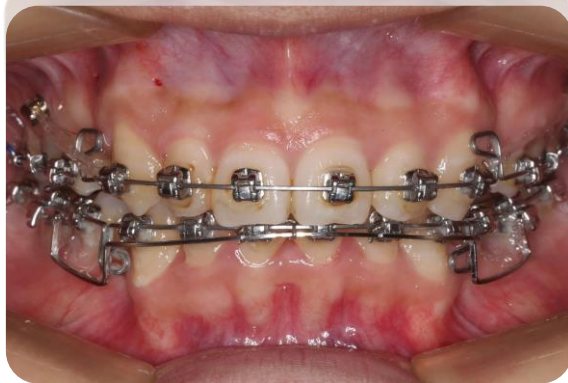
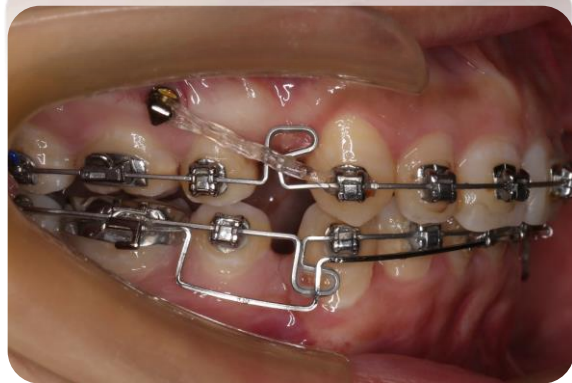
0 months



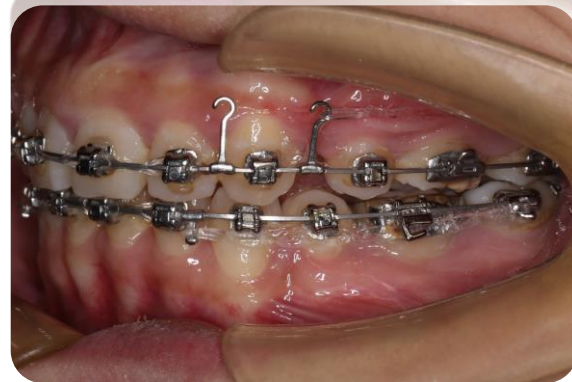
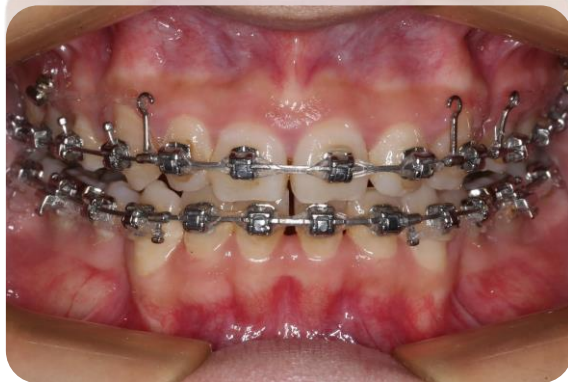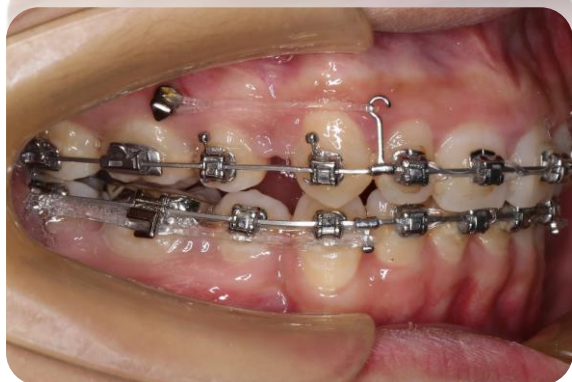5 months



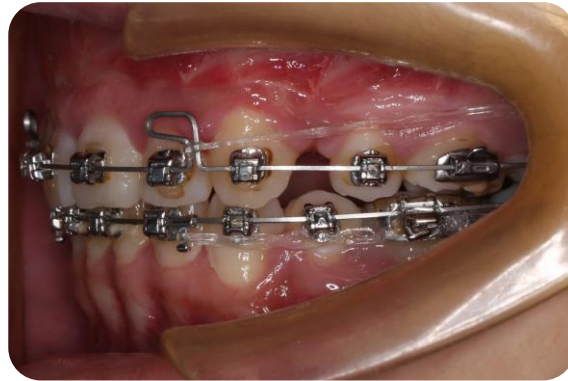
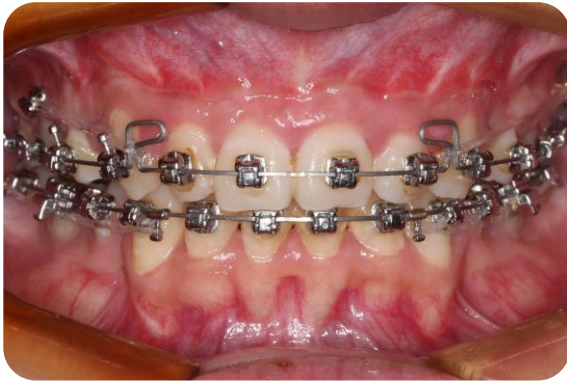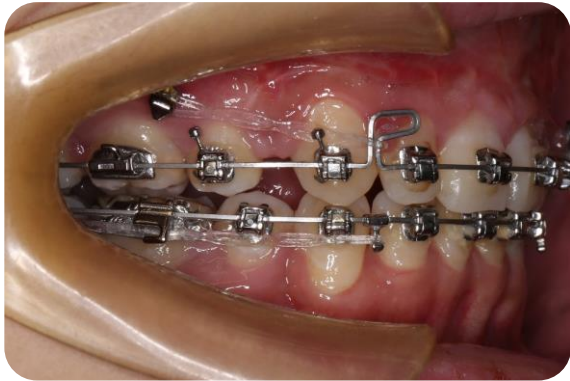
8 months



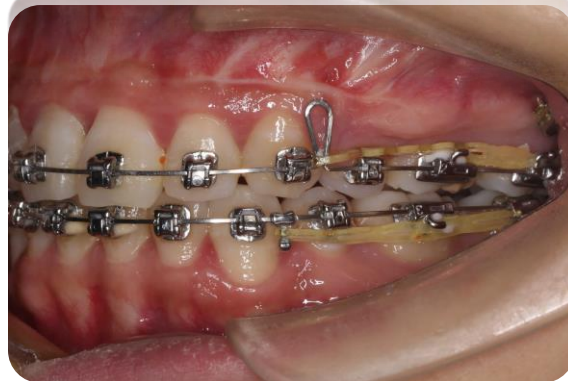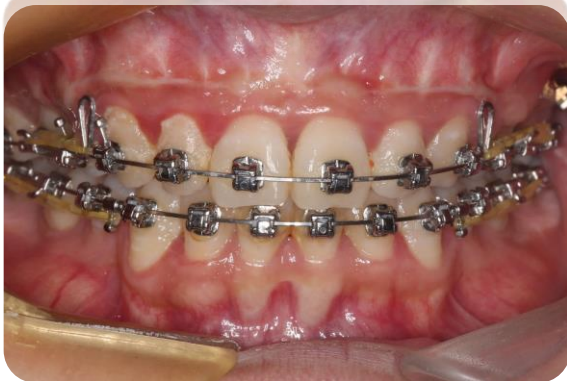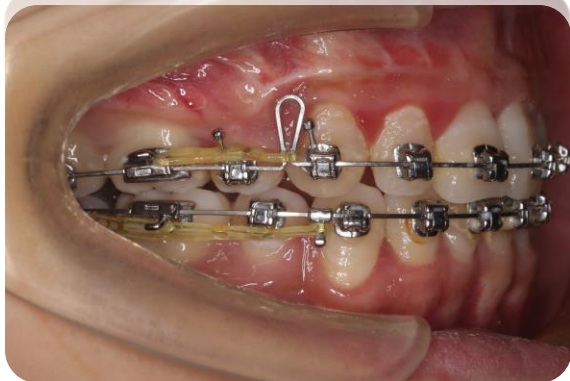
18 months



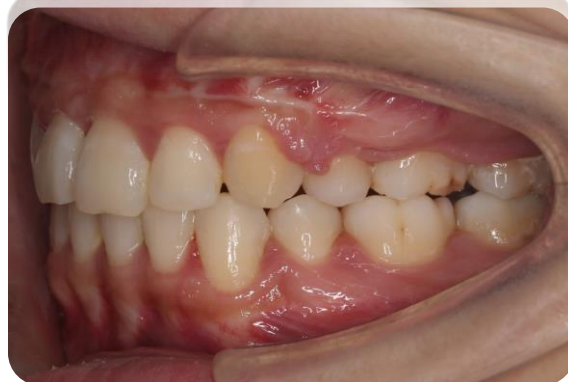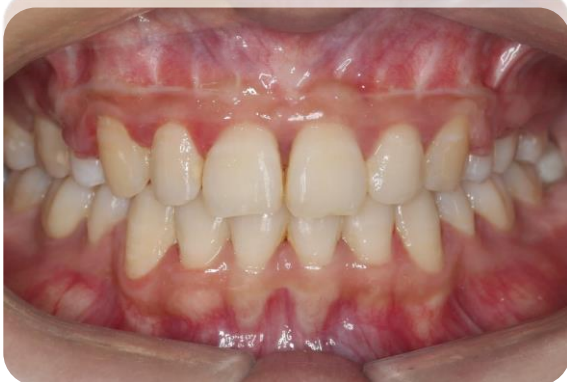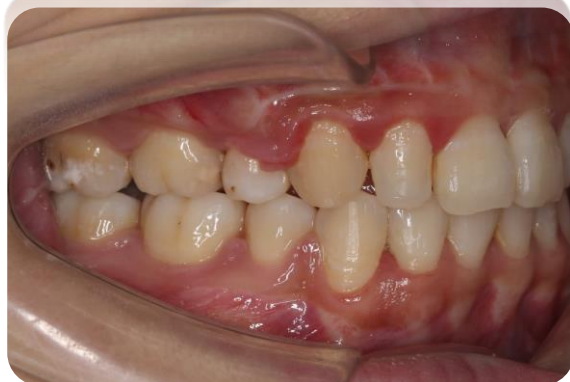23 months



25 months



35 months



37 months



小结体会

病情分析

- 骨性II类 均角
- 严重深覆合 医源性加重
- 上下前牙直立
- 上下前牙区牙槽骨菲薄

治疗方案

- 整平 平导+尖牙正轴+多用途弓
- 根骨关系 PAOO辅助+转矩控制
- 磨牙关系 上颌TAD辅助加强支抗

治疗效果

- 上唇丰满度基本维持，颏唇关系改善
 - 建立中性咬合关系
 - 根骨关系良好，牙周稳定
- 上中线略右偏，后牙宽度欠佳

遗憾



THANK YOU

请各位老师指正